CARTAS AO EDITOR / *LETTERS TO THE EDITOR*

Severe Ocular Toxicity of Quinine in a Ventilated Patient with Severe Malaria: a word of caution

/ C. Nobre / C. Pinto / A. Vieira / T. Ponte / B. Thomas / A. Cardoso / F. Campante

Serviço de Medicina Interna,
Centro Hospitalar Barreiro-Montijo
EPE (CHBM) - Portugal
Unidade de Joaquim Urbano

Corresponding Author:

Carla Nobre
Interna da Formação Específica em Medicina Interna
Centro Hospitalar Barreiro-Montijo, EPE.
Serviço de Medicina Interna
Avenida Movimento das Forças Armadas
2830-094 Barreiro
Portugal
Telemóvel: +351 939 47 45 74
e-mail: carlanobre.med@gmail.com

A 35 year old, Portuguese male of Caucasian descent, working for short periods of time on an offshore oil-platform for the last five years in Angola, presented to the Emergency room five days after returning to Portugal, with fever, chills and rigors and severe headache. Clinical examination revealed a febrile patient, somnolent, but easily arousable, with no significant clinical findings on pulmonary examination. The chest X Ray revealed mild cardiomegaly, prominent interstitial markings principally involving the right lung. Initial laboratory analysis showed a severe thrombocytopenia, hyperbilirubinemia, mainly conjugated with mild elevation of liver enzymes and an elevated PCR. A thick smear revealed multiple stages of *Plasmodium falciparum* with a parasitaemia of about 5% (figure 1).

The patient was started on intravenous quinine and oral doxycycline. He was ventilated for respiratory failure in the Intensive Care Unit (ICU) developing shock and acute renal failure fulfilling criteria for severe malaria under continuous sedation. After extubation, he complained of bilateral painless loss of vision. Ophthalmoscopy revealed pale retina, optic disc pallor and diffusely constricted retinal arterioles. Retinal changes suggestive of malarial

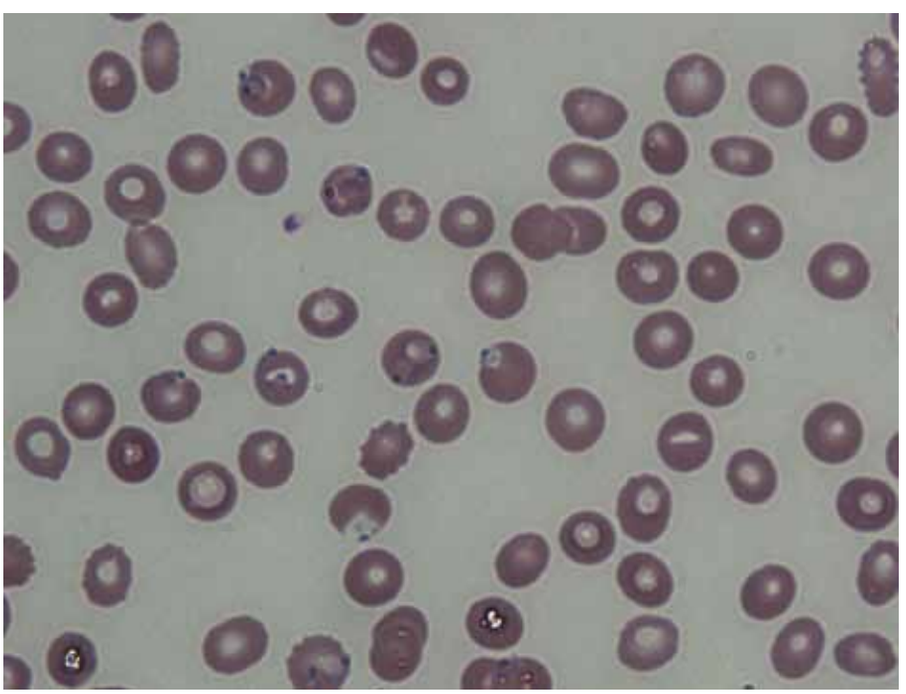

Figura 1: An microscopic image of the thick smear revealing multiple stages of *P. falciparum*.

involvement, namely, retinal whitening and hemorrhages were absent, suggesting quinine toxicity. There were no findings suggestive of cerebral malaria. Lumbar puncture, cranial CT and MR were normal. No cortical potentials were obtained bilaterally during testing for visual evoked potentials (VEPs). After discharge he remains legally blind.

Severe imported falciparum malaria had a mortality of approximately 10% despite the provision of resource-intensive critical care in 45 French ICUs with intravenous quinine the drug used in 98% of these patients while in the South East Asian Quinine Artesunate Malaria Trial (SEAQUAMAT) the mortality in the quinine arm was 22% [1-3] and 15% with intravenous artesunate. Intravenous artesunate is particularly effective because of the rapid clearance of parasitemia. In Portugal, intravenous arthemesinin-combination therapy (ACT) is not available, although recommended by the WHO since 2006 as first-line therapy, and quinine is the usual therapeutic choice[4].

Although intravenous quinine has been used for a long time, it can be associated with serious side effects[5-7]. It has a narrow therapeutic index and concentrations above 5 mg/liter can cause deafness, vertigo, tinnitus, nausea, vomiting, tremors, blurred vision, and malaise. Among the rare and serious effects that mandate dose adjustment are arrhythmias, hypotension, severe visual changes, deafness and hyperinsulinemic hypoglycemia.

Despite the adjustment of the quinine dose to renal function, in cases like our patient with shock on hemodialysis, greater fluctuations in plasma concentrations of drug can occur. Blindness may occur within a few hours, although our patient did not complain of visual loss or difficulties in the initial phase as he was developing ARDS. Vasodilator therapy in the form of calcium channel blockers, nitrates along with immediate withdrawal of the drug is recommended, based on the premise that serious ocular toxicity related to quinine results from retinal ischemia characterized by retinal arteriolar constriction[7]. Unfortunately, no specific vasodilator therapy was used in our patient due to a delay in the diagnosis.

In fact, the delay in diagnosis of ophthalmologic quinine toxicity can occur in all those which, like our patient, are mechanically ventilated in the ICU, under continuous sedation, unable to complain of visual loss. This represents a key aspect to keep in mind when dealing with patients in this situation. It is remarkable that intravenous ACT is still not the standard of care in many developed countries as it is therapeutically superior and less toxic than quinine.

/ References

1. Trampuz A, Jereb M, Muzlovic I, Prabhu RM. Severe malaria. Critical Care. 2003; 7: 315-323.

2. Bruneel F, Tubach F, Corne P et al. Severe imported falciparum malaria: A cohort study in 400 critically ill adults. PLoS ONE. 2010; 5(10): e13236.

3. SEQUAMAT Group. Artesunate versus quinine for treatment of severe falciparum malaria: a randomised trial. Lancet. 2005; 366: 717-25.

4. WHO. Guidelines for the treatment of malaria. 2nd edition. WHO Library 2010.

5. Prasad RS, Kodali VR, Khuraijam GS, et al. Acute confusion and blindness from quinine toxicity. Eur J Emerg Med. 2003; 10: 353-6.

6. Hall AP. Quinine induced blindness. Br J Ophthal. 1997; 81: 1029.

7. Townsend BS, Sturm JW, Whyte S. Quinine associated blindness. Aust Fam Physician. 2004; 33: 627-8.