Revista Portuguesa de Doenças Infecciosas
Imagens em Doenças Infeciosas
Imagens em Doenças Infeciosas / Images in Infectious Diseases 2026 – Volume 20 – Número 2

Amoebic Liver Abscess: simultaneous intestinal and hepatic infection

Abcesso hepático amebiano: envolvimento intestinal e hepático concomitante

Daniela Rodrigues da Silva[1], Rita Patrocínio de Jesus[1].

[1] Serviço de Doenças Infeciosas, Unidade Local de Saúde Amadora/Sintra, Amadora, Portugal

Autor correspondente: Daniela Rodrigues da Silva Email: daniela98silva@hotmail.com

DOI: 10.65332/rpdi.v20.156 Recebido: 16 jul 2026 Aceite: 17 set 2026 Publicado: 26 set 2026

Case Presentation

A 27-year-old man from Cape Verde, who had recently arrived in Portugal, already symptomatic and seeking medical care, presented to the emergency department with a one-month history of right upper-quadrant abdominal pain, diarrhoea and weight loss.

Laboratory testing showed thrombocytosis (platelet count, 722 x 10^9/L), leukocytosis (13.1 x 10^9/L; 70.0% neutrophils), C-reactive protein of 18 mg/dL, gamma-glutamyl transferase 214 International Units per litre (IU/L; reference range 40–130) and alkaline phosphatase 163 IU/L (reference range $\leq$ 60); other liver parameters were within normal range. HIV, hepatitis B, and hepatitis C serologies were negative.

Abdominal contrast-enhanced computed tomography (CT) revealed a large (11 x 9 x 15 cm), homogeneous, hypodense hepatic collection extending to the subhepatic lateral abdominal wall, consistent with a liver abscess (figure 1a). Stool microscopy revealed cysts morphologically compatible with *Entamoeba spp. (histolytica or dispar)*, while stool polymerase chain reaction (PCR) confirmed *E. histolytica*. Serology for *E. histolytica* (IgG) was also positive. Ultrasound-guided drainage yielded greyish, "anchovy-paste"-like material (figure 1b). Direct microscopic examination of the aspirate did not identify trophozoites, and bacterial cultures were negative; PCR of the aspirate confirmed *E. histolytica*.

The patient received metronidazole 750 mg every 8 hours for 10 days followed by paromomycin 500 mg every 8 hours for 7 days (approximately 25-–30 mg/kg/day). Symptoms resolved completely, and post-treatment stool PCR for *E. histolytica* was negative. Follow-up CT performed 9 months after treatment showed complete radiological resolution of the abscess.

Liver abscess is the most common extraintestinal manifestation of *Entamoeba histolytica* infection and predominantly affects young men from endemic regions[1,2]. Since intestinal infection precedes hepatic dissemination, most patients with amoebic liver abscess do not have detectable concurrent intestinal infection at presentation, making the simultaneous detection of *E. histolytica* in stool and liver abscess aspirate a noteworthy finding[1,3,4].

 — © 2026 The Author(s). CC BY 4.0

This case highlights the importance of considering *E. histolytica* in the differential diagnosis of liver abscesses, particularly in patients with a history of residence in or travel to endemic areas, and illustrates the characteristic "anchovy-paste" aspirate associated with amoebic liver abscess. In addition to serology, early stool PCR may provide a rapid, non-invasive means of diagnosis, particularly in patients with gastrointestinal symptoms or when percutaneous drainage is not indicated or feasible, or is delayed. The combination of epidemiological history with microbiological and molecular findings is essential for establishing a timely diagnosis, particularly in non-endemic settings[1,2].

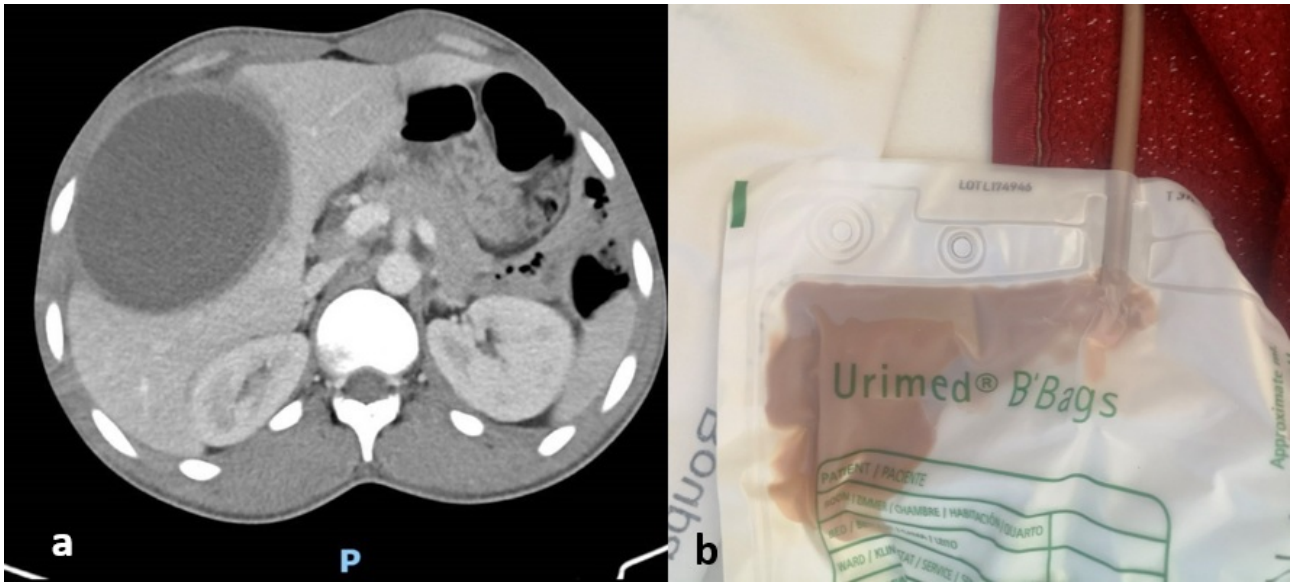

Figure 1. (1a) Contrast-enhanced abdominal computed tomography showing a large (11 x 9 x 15 cm) homogeneous hypodense abscess occupying the right hepatic lobe. (1b) Ultrasound-guided percutaneous drainage yielding the characteristic "anchovy-paste" aspirate of an amoebic liver abscess.

Author Contributions

Daniela Rodrigues da Silva: Conceptualization, Validation, Data collection and analysis, Writing – original draft.

Rita Patrocínio de Jesus: Conceptualization, Writing – review & editing, Supervision.

Funding

No funding was received for this study.

Ethics Statement

This study was conducted in accordance with the ethical principles of the Declaration of Helsinki. Written informed consent was obtained from the patient for publication of clinical details and images.

Conflicts of Interest

All authors report no conflicts of interest relevant to this article.

References

1. Kantor M, Abrantes A, Estevez A, Schiller A, Torrent J, Gascon J, et al. *Entamoeba histolytica*: updates in clinical manifestation, pathogenesis, and vaccine development. *Can J Gastroenterol Hepatol.* 2018;2018:4601420. https://doi.org/10.1155/2018/4601420.

2. Kumanan T, Sujanitha V, Sreeharan N. Amoebic liver abscess: a neglected tropical disease. *Lancet Infect Dis.* 2020;20(2):160–162. https://doi.org/10.1016/S1473-3099(19)30696-6.

3. Wuerz T, Kane JB, Boggild AK, Krajden S, Keystone JS, et al. A review of amoebic liver abscess for clinicians in a nonendemic setting. *Can J Gastroenterol.* 2012;26(10):729–733. https://doi.org/10.1155/2012/852835.

4. Shirley DAT, Haque R, Moonah SN. *Entamoeba* species, including amebic colitis and liver abscess. In: Blaser MJ, Cohen JI, Holland SM, et al., editors. *Mandell, Douglas, and Bennett's Principles and Practice of Infectious Diseases.* 10th ed. Philadelphia: Elsevier; 2026. Chapter 278.