Revista Portuguesa de Doenças Infecciosas
Imagens em Doenças Infeciosas
Imagens em Doenças Infeciosas / Images in Infectious Diseases 2026 – Volume 20 – Número 2

# *Plasmodium falciparum* in a Gram-stained blood culture smear

*Plasmodium falciparum em esfregaço de hemocultura corado pelo Gram*

Yuliana O. Eremina[1†,2,3], Maria Helena Silva Gonçalves[1], Maria Dolores Pinheiro[1].

[1] Clinical Pathology Department, Unidade Local de Saúde de São João, Porto, Portugal
[†] Current affiliation: Clinical Pathology Department, Unidade Local de Saúde de Matosinhos, Matosinhos, Portugal
[2] EPIUnit – Public Health Institute, University of Porto, Porto, Portugal
[3] Laboratory for Integrative and Translational Investigation in Population Health (ITR), Porto, Portugal

**Autor correspondente: Yuliana O. Eremina Email: yuliana.eremina@ulsm.min-saude.pt**

**DOI: 10.65332/rpdi.v20.155 Recebido: 05 jul 2026 Aceite: 31 ago 2026 Publicado: 18 set 2026**

## Case Presentation

A 57-year-old Portuguese man, living in Luanda (Angola) for the past four years, presented to the emergency department after two weeks of fever and two days of vomiting. Physical examination revealed tachypnoea and jaundice of the skin and sclerae. Blood tests showed mild anaemia, hepatic and renal dysfunction, and an elevated C-reactive protein level (252 mg/L); rapid antigen-detection test for malaria was positive for *Plasmodium falciparum* and blood film showed trophozoites with 20.0% parasitaemia.

Blood cultures (two BD BACTEC™ Plus Aerobic/F culture bottles) analysed in the BD BACTEC™ 9240 system became positive after 20 hours of incubation. Gram-stained smear showed no bacteria or fungi but revealed sparse ovoid forms. These forms, showing intense staining at one pole, raised suspicion of *Plasmodium falciparum* trophozoites (figure 1, arrows) and were identified on a Wright-stained smear (figure 2, arrows).

No bacterial growth was detected from blood cultures. The patient was successfully treated with artesunate and artemether-lumefantrine and was asymptomatic at two months of follow-up.

The earliest reported cases of *Plasmodium falciparum*-associated false-positive blood cultures were described in Johannesburg, South Africa[1]. Similar cases were later reported in France, the Netherlands[2], the United States of America[3], and Chile[4]. All cases were attributed to imported malaria. Parasitaemia ranged from 1.8% to 19.0%, and time to blood culture positivity ranged from 3.7 to 42 hours. The positive signal has been attributed to $CO_2$ production resulting from the metabolic activity of *Plasmodium falciparum*, potentially through anaerobic glycolysis and/or the mitochondrial tricarboxylic acid cycle, triggering the fluorescence sensor[1,3]. This phenomenon has also been described with blood culture systems other than the BACTEC™ 9240, suggesting that *Plasmodium falciparum*-associated false-positive blood culture signals may be under-recognised or under-reported in clinical practice, particularly in malaria-endemic areas. Recognition and correct interpretation of this finding may facilitate

 — © 2026 The Author(s). CC BY 4.0 

malaria diagnosis and, especially, help to avoid unnecessary antibiotic use. Only three previously reported cases included similar images[2–4]. Awareness of this unusual finding may be particularly helpful in the context of increasing international migration.

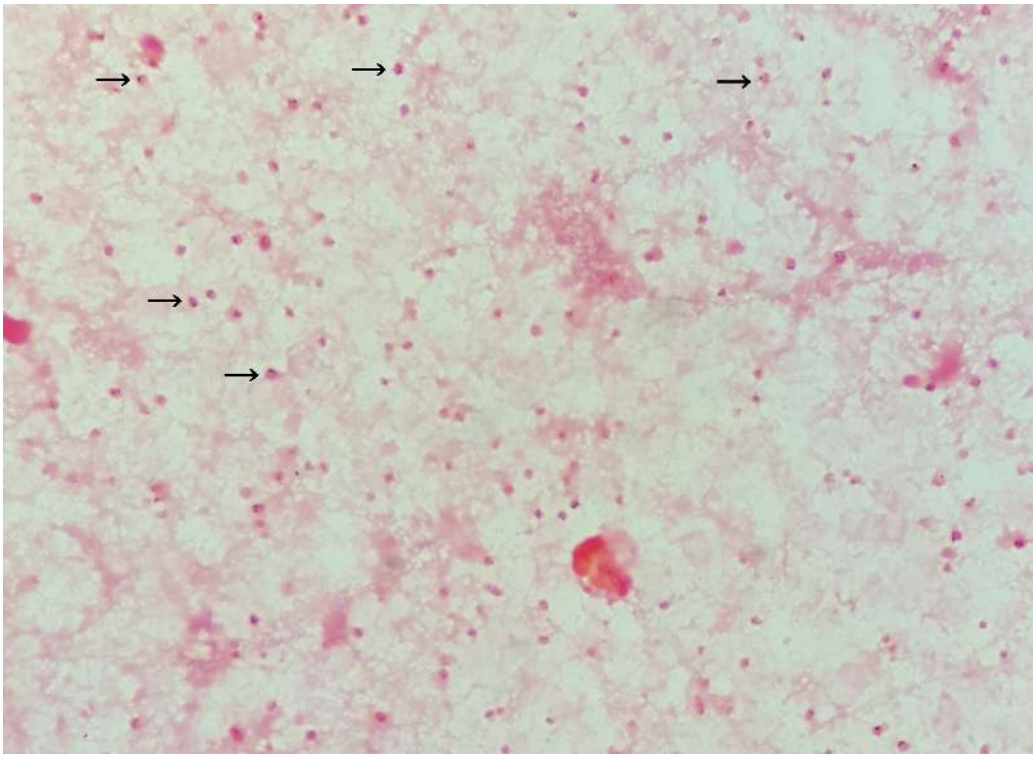

**Figure 1.** Gram-stained smear (×1000) from a blood culture bottle flagged positive, showing *P. falciparum* trophozoites (arrows).

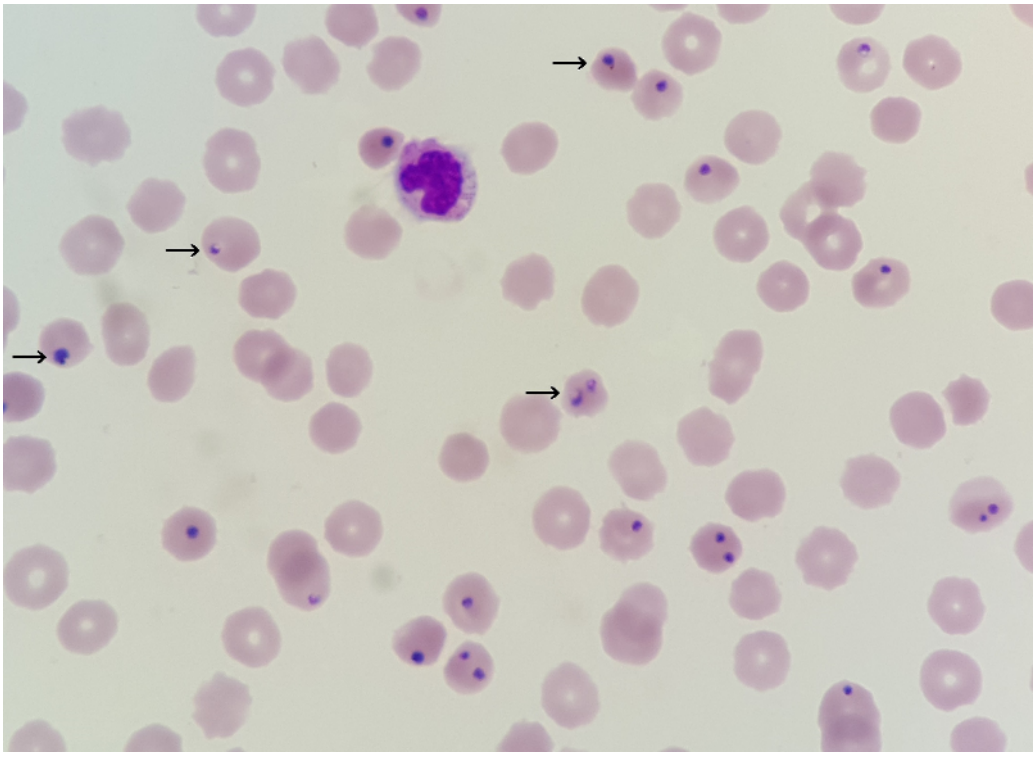

**Figure 2.** Wright-stained smear (×1000) from the same blood culture bottle, showing *P. falciparum* trophozoites (arrows).

 — © 2026 The Author(s). CC BY 4.0 

## Author Contributions

*Yuliana O. Eremina:* Conceptualization, Validation, Writing – original draft, Writing – review & editing, Visualization.

*Maria Helena Silva Gonçalves:* Validation, Writing – review & editing.

*Maria Dolores Pinheiro:* Conceptualization, Validation, Writing – review & editing, Visualization, Supervision.

## Funding

No funding was received for this study.

## Ethics Statement

This study was conducted in accordance with the ethical principles of the Declaration of Helsinki.

The images presented are anonymized laboratory findings (blood culture).

## Conflicts of Interest

All authors report no conflicts of interest relevant to this article.

## References

1. McCarthy KM, Frean J, Loakes J, Liebowitz LD. Growth and maturation of *Plasmodium falciparum* in BacT/Alert blood culture system. *Trans R Soc Trop Med Hyg.* 1999;93(3):272–274. https://doi.org/10.1016/S0035-9203(99)90019-6.

2. de Vries JJ, van Assen S, Mulder AB, Kampinga GA. Positive blood culture with *Plasmodium falciparum*: case report. *Am J Trop Med Hyg.* 2007;76(6):1098–1099. https://doi.org/10.4269/ajtmh.2007.76.1098.

3. Aesif SW, Swierzbinski MJ, Keiser JF. Positive blood culture results after *Plasmodium falciparum* diagnosis. *Lab Med.* 2014;45(2):e89–e91. https://doi.org/10.1309/LM8BLDCRH6WT0VPP.

4. Weitzel T, Porte L. *Plasmodium falciparum* and blood cultures: 'rings' a bell? *Clin Microbiol Infect.* 2022;28(8):1097–1098. https://doi.org/10.1016/j.cmi.2021.09.024.

 — © 2026 The Author(s). CC BY 4.0 