Revista Portuguesa de Doenças Infecciosas
Relato de Casos Clínicos
Relato de Casos Clínicos / Case Reports 2026 – Volume 20 – Número 2

Cerebral malaria with extremely low parasitaemia: rare but real

Malária cerebral com parasitémia extremamente baixa: um caso raro, mas real

Ana Catarina Rodrigues[1], Catarina Rodrigues[1], Miguel Miguel[2], Silvia Coelho[3]

[1] Serviço de Doenças Infeciosas, Unidade Local de Saúde Amadora/Sintra, Amadora, Portugal
[2] Serviço de Patologia Clínica, Unidade Local de Saúde Amadora/Sintra, Amadora, Portugal
[3] Serviço de Medicina Intensiva, Unidade Local de Saúde Amadora/Sintra, Amadora, Portugal

Autor correspondente: Ana Catarina Rodrigues Email: aclcrodrigues@gmail.com

DOI: 10.65332/rpdi.v20.141 Recebido: 19 jan 2026 Aceite: 07 jun 2026 Publicado: 08 set 2026

ABSTRACT

Introduction: Malaria is a disease caused by the protozoan *Plasmodium* which, if left undiagnosed and untreated, may lead to severe outcomes. Cerebral malaria is a potentially fatal presentation marked by impaired consciousness due to microvascular obstruction from sequestered infected erythrocytes.

Case Presentation: We describe a case of a 49-year-old woman from Angola, who travelled to Portugal one month before hospital admission and was diagnosed with cerebral malaria despite extremely low parasitaemia (0.4%) at presentation. This finding led to the consideration of differential diagnoses at first. The degree of parasitaemia was reassessed 14 hours later, showing a dramatic increase to 19%.

Discussion: We propose that the endothelial binding of infected red blood cells leads to sequestration within small cerebral vessels, thereby removing parasites from the peripheral circulation and explaining the dissociation between the low-grade parasitaemia and the severity of the neurological picture.

Conclusion: Rapid diagnosis through thin and thick blood smears is essential, and repeated blood sampling is critical for accurate diagnosis and effective management. If clinical suspicion of severe malaria is high, prompt treatment should be initiated regardless of calculated parasitaemia.

Keywords: Cerebral Malaria; *Plasmodium falciparum*; Sequestration.

 — © 2026 The Author(s). CC BY 4.0

RESUMO

Introdução: A malária é uma doença causada pelo protozoário do género *Plasmodium*, que pode causar doença grave quando diagnosticada tardiamente. A malária cerebral é uma apresentação potencialmente fatal caracterizada pela obstrução microvascular decorrente do sequestro de eritrócitos parasitados.

Descrição do Caso: Apresenta-se o caso de uma mulher de 49 anos, natural de Angola, que viajou para Portugal no mês anterior à admissão hospitalar e foi diagnosticada com malária cerebral, apesar de apresentar um valor de parasitémia muito baixo (0,4%), o que suscitou inicialmente a consideração de diagnósticos diferenciais. Foi repetida a medição de parasitémia 14 horas depois, com uma elevação súbita para 19,0%.

Discussão: Acreditamos que a ligação endotelial dos eritrócitos parasitados tenha desencadeado o sequestro nos capilares sanguíneos cerebrais, removendo os parasitas da circulação periférica, justificando a dissociação entre a baixa parasitémia e a gravidade dos sintomas neurológicos.

Conclusão: A realização de esfregaço de gota fina e espessa é essencial para o diagnóstico de malária, sendo muitas vezes necessária a repetição em diferentes amostras colhidas ao longo do tempo. Sempre que houver suspeita clínica de malária grave, deverá ser iniciado tratamento atempado, independentemente do valor de parasitémia.

Palavras-Chave: Malária cerebral; *Plasmodium falciparum*; Sequestro.

Introduction

Malaria is an arthropod-borne infectious disease caused by protozoan parasites of the genus *Plasmodium*, primarily transmitted through the bite of *Anopheles* mosquitoes. There are five *Plasmodium* parasite species that cause malaria in humans (*P. falciparum*, *P. ovale*, *P. vivax*, *P. malariae* and *P. knowlesi*). *P. falciparum* is the deadliest malaria parasite and the most prevalent in the African continent[1].

A diagnosis of malaria should be considered in any traveller coming from an endemic malaria area, even with non-specific symptoms. The gold standard for malaria diagnosis is still thin and thick blood smears. To prevent severe complications of *Plasmodium* infection, timely and accurate diagnosis is crucial. Both clinicians and laboratory professionals play a vital role in this process, with the laboratory being essential for the prompt detection of the parasite in the blood, species identification and, if indicated, parasitaemia calculation, enabling effective and targeted treatment[2].

Cerebral malaria is a form of severe malaria and is defined by the World Health Organization (WHO) as a clinical syndrome characterised by coma or impaired consciousness in a patient with *Plasmodium falciparum* malaria, in the absence of other causes of encephalopathy, such as hypoglycaemia, seizures, sepsis, or stroke[3]. The patient with cerebral malaria typically shows other severity criteria such as high parasitaemia, jaundice, and renal failure. Nonetheless, severe malaria with organ dysfunction can occur even in cases of low parasitaemia and, if left untreated, has a high mortality rate, nearly 30% in adults[1].

The pathogenesis of coma in severe malaria due to *Plasmodium falciparum* remains poorly understood. Endothelial binding of infected red blood cells (RBCs) leading to their sequestration within small vessels and partial obstruction of the brain microvasculature represents one mechanism that could contribute to coma in cerebral malaria. Mechanisms of microvascular disease include formation of sticky knobs on the cell sur-

 — © 2026 The Author(s). CC BY 4.0

face and rosetting (e.g., adherence of infected RBCs to uninfected cells, forming rosettes that clog microcirculation)[4,5].

In patients with *Plasmodium falciparum* malaria, several parasites are sequestered in tissue capillaries as part of the asexual life cycle and may not always be present in the peripheral blood. Thus, a *P. falciparum* infection might be missed unless blood samples are repeated at least daily, or as often as the clinical picture dictates [2].

Case Presentation

In January 2024, a 49-year-old female was admitted with a three-day history of altered behaviour, mutism, fever, abdominal pain, and vomiting. The woman was originally from Angola, living in Portugal since the previous month.

Upon hospital admission, she was prostrated, unresponsive to commands, and reacted only to painful stimuli (Glasgow Coma Score of 10 points). Laboratory tests showed microcytic and hypochromic anaemia (haemoglobin 10 g/dL), elevated inflammatory markers (white blood cell count 13.6 × 10^9/L with 80.0% neutrophils, C-reactive protein 230 mg/L), total bilirubin of 11.0 mg/dL, direct bilirubin 7.5 mg/dL; acute kidney injury, stage 1 with serum creatinine 1.3 mg/dL and serum urea 76.2 mg/dL; arterial blood gas analysis showed uncompensated respiratory alkalosis and hyperlacticaemia. The brain and abdominal CT scan showed no abnormalities.

Considering her epidemiological history and the results of the blood tests, a rapid immunochromatographic malaria diagnostic test (BinaxNOW® MALARIA) was performed and was positive for both HRP2 (histidine-rich protein 2, antigen specific to *Plasmodium falciparum*) and pan-malarial antigen. An oral artemisinin-based regimen was initiated, and thin blood smears were prepared and stained with Giemsa to identify the *Plasmodium* species and assess parasitaemia, revealing the presence of *P. falciparum* in 4/1000 RBCs (0.4%).

The patient was admitted to the intensive care unit with suspected severe malaria with cerebral involvement. The patient's consciousness deteriorated, requiring orotracheal intubation and invasive mechanical ventilation for airway protection.

Considering the presence of severity criteria and after consulting with an Infectious Diseases Specialist, the treatment was changed to artesunate (2.4 mg/kg) within 6 hours of hospital admission. Concurrently, empirical antibiotic therapy with amoxicillin/clavulanate was initiated for suspected aspiration pneumonia. An EEG was performed and showed no paroxysmal activity, suggesting metabolic encephalopathy.

A second thin blood smear evaluation was performed 14 hours after, showing *P. falciparum* trophozoites (Figure 1a) and hemozoin clumps inside the leucocytes (Figure 1b), with a parasitaemia of 190/1000 RBC (19%). Evolution of parasitaemia levels is shown in Figure 2.

The patient completed four administrations of artesunate (2.4 mg/kg/dose at hour 0, 12, 24, and 48), followed by a course of artemether/lumefantrine once oral treatment was tolerated. She was given amoxicillin/clavulanic acid for seven days. Afterwards, clinical improvement was seen, allowing the patient to be extubated and transferred to the Infectious Diseases ward.

Worsening anaemia persisted despite several transfusions (Day 1: Hb 10.0 g/dL, LDH 808 U/L, haptoglobin <10 mg/dL; Day 5: Hb 6.2 g/dL; Day 18: Hb 6.1 g/dL, LDH 1133 U/L, haptoglobin <10 mg/dL). Given the early and marked haemoglobin decline, haemolysis was considered more likely related to the underlying infection, with delayed artesunate-induced haemolysis remaining a possible contributing factor.

 — © 2026 The Author(s). CC BY 4.0

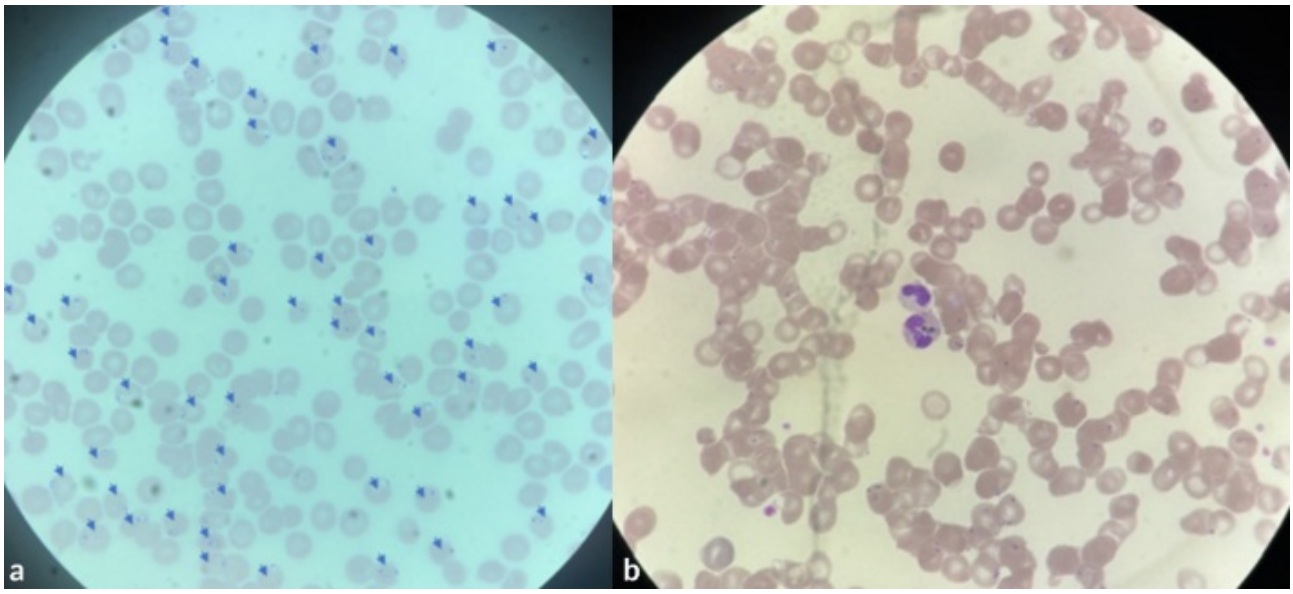

Figure 1. a) Ring-form trophozoites of *P. falciparum* (parasitaemia ∼ 19%); b) Hemozoin clumps inside neutrophils.

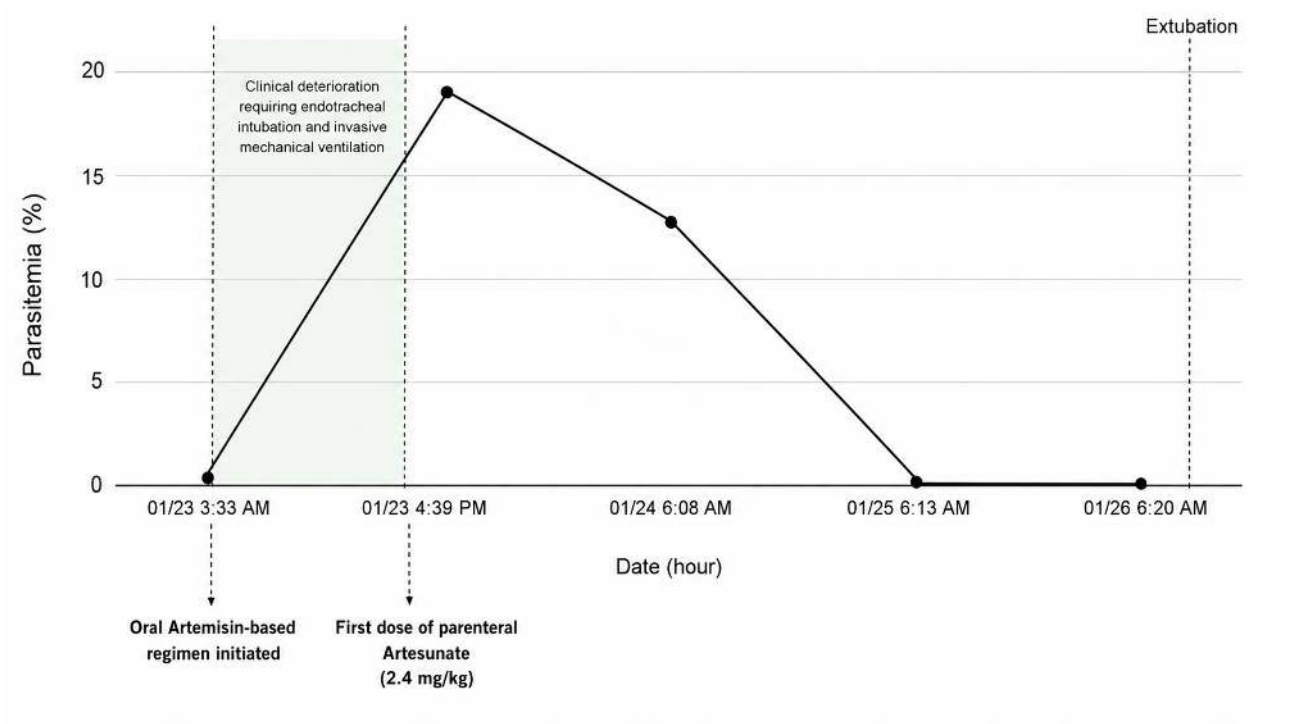

Figure 2. Evolution of parasitaemia levels over time.

After stabilising haemoglobin levels and completion of antibiotic treatment with resolution of respiratory failure, the patient was discharged on the 21st day of hospitalisation and referred to the Infectious Diseases Outpatient Clinic.

Discussion

Cerebral malaria typically affects children, pregnant women, and immunocompromised individuals[7], whereas the presented clinical case reports a patient from an endemic area where partial immunity to *P. falciparum* would typically be expected, reducing the likelihood of severe infection.

In some malaria-endemic regions, the intensity of transmission is so high that part of the population harbors the parasite without developing clinical illness. These individuals may acquire partial immunity due to repeated exposures which protect them from severe symptoms of malaria, but not from the infection itself. Hence, they may exhibit asymptomatic parasitaemia. Accordingly, the identification of malaria parasites in a symptomatic patient does not necessarily indicate that the parasites are the cause of the illness. Currently, no diagnostic test can differentiate between parasitaemia causing clinical malaria and febrile illness from another cause in a patient who also has asymptomatic parasitaemia. Given the severity of the clinical presentation and the low-grade parasitaemia in a patient with chronic exposure, alternative diagnoses were considered[1].

Even under ideal conditions, the accuracy of microscopic examination of stained blood smears depends on optimal film preparation, availability of an experienced observer, and always carries the possibility of human error. Nevertheless, light microscopy of thick and thin stained blood smears remains the gold standard method for diagnosing malaria. Thick smears can be 20–40 times more sensitive than thin smears for screening of *Plasmodium* parasites, with a detection limit usually beginning at 10–50 trophozoites/µl (corresponding to 1 to 2/1000 or 0,1 to 0,2% infected RBC)[8]. On the other hand, thin smears allow one to identify malaria species (including the diagnosis of mixed infections), quantify parasitaemia, and assess the presence of schizonts, gametocytes, and malarial pigment in neutrophils and monocytes[9–11]. Microscopy cannot reliably detect very low parasitaemia (<5 to 10 parasites/µL), including in cases where most of the parasite biomass is sequestered (e.g., in the case of placental sequestration during pregnancy)[11]. If malaria is suspected and the initial smear is negative, additional smears should be prepared and examined over the subsequent 48 to 72 hours[10]. The Centers for Disease Control and Prevention (CDC) recommend repeating a thick and thin smear every 12 to 24 hours for a total of three sets before ruling out malaria[12,13]. The diagnostic standard procedure in the laboratory of our institution is to associate thin smears and the BinaxNOW™ Malaria test, considering its sensitivity (53.9% to 99.7%, for parasitaemia 0–100 to >5000/µL, respectively) and specificity (94.2%) for *P. falciparum*[14].

Disease progression to severe malaria may take days but can also occur within a few hours; thus the diagnosis should be established as soon as possible. To make an early diagnosis of cerebral malaria and promptly initiate treatment, clinicians should have a high index of suspicion in patients presenting with unresolved headaches, seizures, or behavioural changes, particularly if they are travellers coming from malaria-endemic areas. Although typically associated with high levels of parasitaemia[15], cerebral malaria may be present with hypoparasitaemia due to sequestration of the parasite in the central nervous system, a poor prognostic sign. Severe complications are the result of dysregulation in microcirculation as well as direct metabolic disturbances caused by the parasite's presence, which can lead to fatal outcomes. Patients like the one described, requiring mechanical ventilation and vasopressor support, have a higher mortality rate. Prompt treatment with artesunate should be started as soon as possible to improve neurocognitive outcomes, as mortality from cerebral malaria is high, reaching 30,0%[7].

Conclusion

This case highlights the need for decisively initiating treatment in patients with suspected severe malaria regardless of calculated parasitaemia, as well as the need for understanding laboratory test results as supportive of clinical decisions, while fully conscious of the specificities of the methods and possible pitfalls.

Author Contributions

Ana Catarina Rodrigues: Conceptualisation; Methodology; Investigation; Formal Analysis; Data Curation;

Writing - Original Draft; Writing - Review & Editing; Supervision.

Catarina Rodrigues and Sílvia Coelho: Writing - Original Draft; Writing - Review & Editing.

Miguel Miguel: Formal Analysis; Writing - Original Draft; Writing - Review & Editing.

Funding

No funding was received for this study.

Ethics Statement

This study was conducted in accordance with the ethical principles of the Declaration of Helsinki.

Written informed consent was obtained from the patient for publication of clinical details and images.

Conflicts of Interest

The authors declare no conflicts of interest.

References

1. Song X, Wei W, Cheng W, Zhu H, Wang W, Dong H, et al. Cerebral malaria induced by *Plasmodium falciparum*: clinical features, pathogenesis, diagnosis, and treatment. *Front Cell Infect Microbiol.* 2022;12:1–14. https://doi.org/10.3389/fcimb.2022.939532
2. Poespoprodjo J, Douglas N, Ansong D et al. Malaria. *The Lancet.* 2023;402:2328-2345. https://doi.org/10.1016/S0140-6736(23)01249-7
3. WHO guidelines for malaria. Geneva: World Health Organization; 2025. https://doi.org/10.2471/B09514
4. White NJ, Turner GDH, Day NPJ, Dondorp AM. Lethal malaria: Marchiafava and Bignami were right. *J Infect Dis.* 2013;208(2):192–198. https://doi.org/10.1093/infdis/jit116.
5. Ndunge O, Kilian N, Salman M. Cerebral malaria and neuronal implications of *Plasmodium falciparum* infection: from mechanisms to advanced models. *Adv Sci (Weinh).* 2022;9(36):e2202944. https://doi.org/10.1002/advs.202202944.
6. Albrecht-Schgoer K, Lackner P, Schmutzhard E, Baier G. Cerebral malaria: current clinical and immunological aspects. *Front Immunol.* 2022;13:1–11. https://doi.org/10.3389/fimmu.2022.863568
7. Trampuz A, Jereb M, Muzlovic I, Prabhu RM. Clinical review: severe malaria. *Crit Care.* 2003;7(4):315–323. https://doi.org/10.1186/cc2183
8. Mishra SK, Newton CRJC. Diagnosis and management of the neurological complications of *falciparum* malaria. *Nat Rev Neurol.* 2009;5(4):189–198. https://doi.org/10.1038/nrneurol.2009.23
9. Moody A. Rapid diagnostic tests for malaria parasites. *Clin Microbiol Rev.* 2002;15(1):66–78. https://doi.org/10.1128/CMR.15.1.66-78.2002.
10. Rogers CL, Bain BJ, Garg M, Fernandes S, Mooney C, Chiodini PL. British Society for Haematology guidelines for the laboratory diagnosis of malaria. *Br J Haematol.* 2022;197(3):271–282. https://doi.org/10.1111/bjh.18092.
11. Bruce-Chwatt LJ. DNA probes for malaria diagnosis. *Lancet.* 1984;323(8380):795. https://doi.org/10.1016/S0140-6736(84)91308-4.
12. White NJ. The treatment of malaria. *N Engl J Med.* 1996;335(11):800–806. https://doi.org/10.1056/NEJM199609123351107.
13. Centers for Disease Control and Prevention (CDC). Treatment of malaria (guidelines for clinicians). 2013;1–8. https://stacks.cdc.gov/view/cdc/27961.
14. Murray CK, Gasser RA, Magill AJ, Miller RS. Update on rapid diagnostic testing for malaria. *Clin Microbiol Rev.* 2008;21(1):97–110. https://doi.org/10.1128/CMR.00035-07.
15. Mseza B, Kumbowi PK, Nduwimana M, Banga D, Busha ET, Egesa WI, Odong RJ, Ndeezi G. Prevalence and factors associated with cerebral malaria among children aged 6 to 59 months with severe malaria in Western Uganda: a hospital-based cross-sectional study. *BMC Pediatr.* 2024;24(1):704. https://doi.org/10.1186/s12887-024-05178-z.