Revista Portuguesa de Doenças Infecciosas
Revisão Clínica
Revisão Clínica / Clinical Review 2026 – Volume 20 – Número 1

Balancing Scalpel and Antibiotics: A Modern Approach to Bone and Joint Infection Management

Entre a Cirurgia e Antibióticos: Abordagem ao Tratamento das Infeções Ósseas e Articulares

Tiago Torres[1], Manuel Vallarta[2], Miguel Araújo Abreu[3], Ricardo Sousa[4].

[1] Serviço de Ortopedia, Hospital Ortopédico de Sant'Ana, Lisboa, Portugal
[2] Serviço de Ortopedia, Clínica Hospital ISSSTE Constitución, Monterrey, México
[3] Serviço de Infeciologia, Unidade Local de Saúde de Santo António, Porto, Portugal
[4] Serviço de Ortopedia, Unidade Local de Saúde de Santo António, Porto, Portugal

Autor correspondente: Tiago Torres **Email: tiago.ap.torres96@gmail.com**

DOI:10.65332/rpdi.v20.138 **Recebido: 15 jan 2026** **Aceite: 16 mar 2026** **Publicado: 24 mar 2026**

ABSTRACT

Background: Bone and joint infections are challenging musculoskeletal conditions, often associated with high morbidity and functional impairment. Implant-associated infections are particularly difficult to treat due to biofilm-mediated bacterial resistance.

Objective: To provide an interdisciplinary algorithm for the management of bone and joint infections, including guidance on implant retention or removal.

Context: Current evidence on septic arthritis, osteomyelitis, fracture-related infections, and prosthetic joint infections was reviewed. Core management principles include radical debridement, microbiological sampling, stabilization, soft tissue coverage, and tailored antibiotic therapy. Treatment strategies depend on implant presence and infection chronicity, including debridement, antibiotics, and implant retention (DAIR), staged revision, or suppressive antibiotic therapy.

Key concepts: Implant-free infections are treated with extensive debridement and six weeks of antibiotic therapy. Acute implant-associated infections may be managed with DAIR combined with anti-biofilm antibiotics, achieving cure rates of 60.0 – 90.0% under optimal conditions. Chronic infections or mature biofilm typically require staged implant removal and reconstruction. While single-stage revision is feasible in selected cases, two-stage procedures remain standard for complex infections. Antimicrobial duration should be individualized according to clinical response.

Conclusion: Successful management relies on a multidisciplinary approach integrating surgical and medical strategies. Individualized therapy based on implant status, biofilm presence, and patient-specific factors is essential to maximize infection eradication and functional recovery.

Keywords: Prosthetic joint infection; Fracture-related infection; Orthopaedic infection algorithm.

 — © 2026 The Author(s). CC BY 4.0

RESUMO

Contexto: As infeções osteoarticulares estão frequentemente associadas a elevada morbilidade e impacto funcional. O tratamento de infeções associadas a implantes é particularmente complexo devido à resistência bacteriana mediada por biofilme.

Objetivo: Fornecer um algoritmo interdisciplinar para a abordagem das infeções osteoarticulares, incluindo orientações relativas à retenção ou remoção de implantes.

Contexto científico: Foi revista a evidência atual relativa à artrite séptica, osteomielite, infeções relacionadas com fraturas e infeções protésicas. Os princípios fundamentais do tratamento incluem desbridamento radical, colheita de amostras microbiológicas, estabilização, cobertura adequada dos tecidos moles e antibioterapia dirigida. As estratégias terapêuticas dependem da presença de implantes e da cronicidade da infeção, incluindo procedimentos de desbridamento, antibioterapia e retenção do implante (DAIR), revisão em um ou dois tempos, ou terapêutica antibiótica supressiva.

Conceitos-chave: As infeções sem implante são tratadas com desbridamento extensivo e seis semanas de antibioterapia. As infeções agudas associadas a implantes podem ser tratadas com DAIR e antibióticos com atividade anti-biofilme, alcançando taxas de cura entre 60,0 – 90,0% em condições ideais. As infeções crónicas ou com biofilme maduro geralmente requerem a remoção do implante em etapas e a reconstrução subsequente. Embora a revisão em um único tempo seja viável em casos selecionados, os procedimentos em dois tempos continuam a constituir a abordagem preferencial no tratamento de infeções complexas. A duração da antibioterapia deve ser individualizada de acordo com a resposta clínica.

Conclusão: O sucesso do tratamento depende de uma abordagem multidisciplinar que integre estratégias cirúrgicas e médicas. A individualização da terapêutica, baseada no estado do implante, na presença de biofilme e em fatores específicos do doente, é essencial para maximizar a erradicação da infeção e a recuperação funcional.

Palavras-Chave: Infeção associada a prótese articular; Infeção associada a fratura; Algoritmo para abordagem da infeção ortopédica.

Introduction

Bone and joint infections are among the most challenging conditions in orthopaedic practice and are associated with high morbidity and functional impairment. Their epidemiology has evolved markedly over recent decades. While primary haematogenous infections have become less common due to early diagnosis and effective antibiotic therapy, secondary infections – particularly postoperative – now dominate clinical practice. Currently, prosthetic joint infections (PJI) and fracture-related infections (FRI) are the two major types of bone and joint infections. This shift is driven by the increasing number of surgical procedures, greater patient complexity, and expanding use of permanent implants such as prosthetic joints and fracture fixation devices[1,2].

The global incidence of PJI after primary arthroplasty is likely underestimated, with reported rates around 0.5% for total hip arthroplasty and 1.0 – 2.0% for total knee arthroplasty, depending on diagnostic criteria and follow-up[3]. PJI is the second most frequent complication after aseptic loosening and remains one of the most devastating complications of arthroplasty[4]. FRI is defined as any infection occurring in the context of a fracture, including early infections, infected non-unions, and haematogenous infections[2,5,6,7]. In this context,

 — © 2026 The Author(s). CC BY 4.0

and as a practical consideration, a fracture treated with osteosynthesis hardware that progresses to non-union should be regarded as highly suspicious for infection until proven otherwise. Reported rates range from 1.0 – 2.0% in closed fractures to over 30.0% in high-grade open fractures, with recurrence rates between 10.0% and 21.0%[6,8].

A critical determinant in these infections is the presence of an implant, which profoundly influences both the pathophysiology and the therapeutic approach[6]. Implants provide a substrate for biofilm formation, a highly organised microbial community encased in a self-produced extracellular matrix[9,10]. This biofilm adheres firmly to prosthetic and bony surfaces and allows microorganisms to persist at low metabolic activity and in low inoculum, triggering only a limited and highly localised inflammatory response. As a result, these infections often fail to meet traditional diagnostic criteria and may be easily overlooked or misinterpreted. In addition, bacteria embedded within biofilms are significantly resistant to host immune defences and antimicrobial agents, making the elimination of infection via conservative or antibiotic-only strategies virtually impossible. Understanding the biofilm paradigm is essential to guide the timing and extent of surgical debridement, as well as to optimise antimicrobial regimens[10,11]. Infection duration, biofilm maturation, and the overall therapeutic objective are key determinants of treatment strategy. In selected cases—such as suppressive management of infection in stable fractures—implant retention may be achieved despite presumed biofilm presence to allow fracture consolidation before hardware removal. Importantly, although time from symptom onset is a relevant parameter, it does not solely dictate biofilm maturation. Biofilm formation and structural complexity are dynamic processes that are significantly influenced by the virulence and biological behaviour of the causative pathogen. This interaction may be particularly consequential in borderline presentations where differentiation between acute and chronic infection remains ambiguous[3,5,8].

Beyond biofilm biology, bone and joint infections frequently arise in mechanically unstable or biologically compromised environments—characterised by devitalized soft tissues, necrotic bone, and/or structural defects. Under these conditions, antibiotic therapy alone is insufficient and predictably leads to persistent infection, chronicity, antimicrobial resistance, and progressive functional decline[5,8,12].

Effective management requires early and coordinated care by a multidisciplinary team that includes not only orthopaedic surgeons and infectious disease specialists but also other complementary surgical and medical specialties, such as plastic surgery, microbiology, and internal medicine[13].

Successful outcomes require adherence to universal surgical and antibiotic therapy principles and clinical decision-making according to structured algorithms. This article synthesises interdisciplinary treatment principles for bone and joint infections in adult patients into a practical algorithm, and illustrates its application through representative clinical scenarios.

1. Fundamental Principles

As outlined above, achieving curative treatment in bone and joint infections almost invariably requires surgical intervention[5,14,15]. This process must follow an assertive, logical, and structured framework that integrates surgical decision-making with microbiological and pharmacological expertise[15,16]. Effective infection control and functional restoration depend on the consistent application of several core principles:

Radical Debridement

Debridement is the cornerstone of treatment and must include removal of all infected and devitalized tissues, including bone, implants, prostheses, and surrounding soft tissue. No antibiotic regimen is effective in the presence of dead tissue or mature biofilm[3,5,17,18].

Rigorous Microbiological Sampling

Multiple deep tissue samples should be systematically obtained for microbiological analysis, ideally during surgery and before any antibiotic exposure. This approach helps minimise the risk of false-negative culture results and ensures a more accurate identification of the causal pathogen[11,16]. It is critical that microbiological sampling be performed after a minimum of two-week antibiotic-free period[16,19,20]. Intraoperative sampling provides the highest diagnostic yield and should be prioritised. Preoperative superficial swabs should be avoided, as they correlate poorly with intraoperative culture results and offer limited diagnostic reliability[16].

Dead Space Management

After debridement, dead space must be eliminated or filled to prevent recurrence. Options include muscle flaps, antibiotic-loaded cement spacers, or resorbable local antibiotic carriers such as calcium sulfate beads, hydroxyapatite-based bone substitute, etc.[17,21–23].

Mechanical Stability

Infection cannot be eradicated in a mechanically unstable environment. Achieving adequate stability may require the use of joint spacers, external fixation, or the placement of new internal implants, depending on the clinical scenario[5,8,12].

Soft-Tissue Coverage

Well-vascularized soft tissues are critical for effective antibiotic penetration, control of local inflammation, and protection of underlying implants. When native soft-tissue integrity is insufficient, local or free flap reconstruction may be required to restore an optimal biological environment[17].

Antimicrobial Therapy

Only after all these steps have been adequately addressed can systemic antibiotic therapy achieve its intended effect. The choice and duration of treatment depend primarily on whether an implant is present, the isolated microorganism, and the spectrum of viable antibiotic options—each of which must be carefully aligned with the patient's comorbidities and pharmacological limitations. When an implant is retained, agents with anti-biofilm activity are mandatory, such as rifampicin-based combinations for *Staphylococcus spp.* or fluoroquinolones for Gram-negative organisms. Rifampicin therapy should be initiated only under appropriate clinical conditions, such as a dry surgical wound and favourable local progression, and should not be started in the immediate postoperative period. Surgical and antibiotic strategies are mutually interdependent[9–11,24–27]. The impact of tailored antibiotic strategies and structured multidisciplinary management on outcomes in PJI has been recently reinforced by contemporary outcomes analyses[24].

Functional Reconstruction

The goal in managing bone and joint infections is not solely to eradicate the infection but to preserve or restore movement, stability, and overall limb function[15,17].

2. Algorithm for the management of bone and joint infections

The management of bone and joint infections requires a structured and methodical decision-making process. Figure 1 outlines a rationale that strengthens shared interdisciplinary decision-making, streamlines communication, and harmonises goals among the involved specialties.

 — © 2026 The Author(s). CC BY 4.0

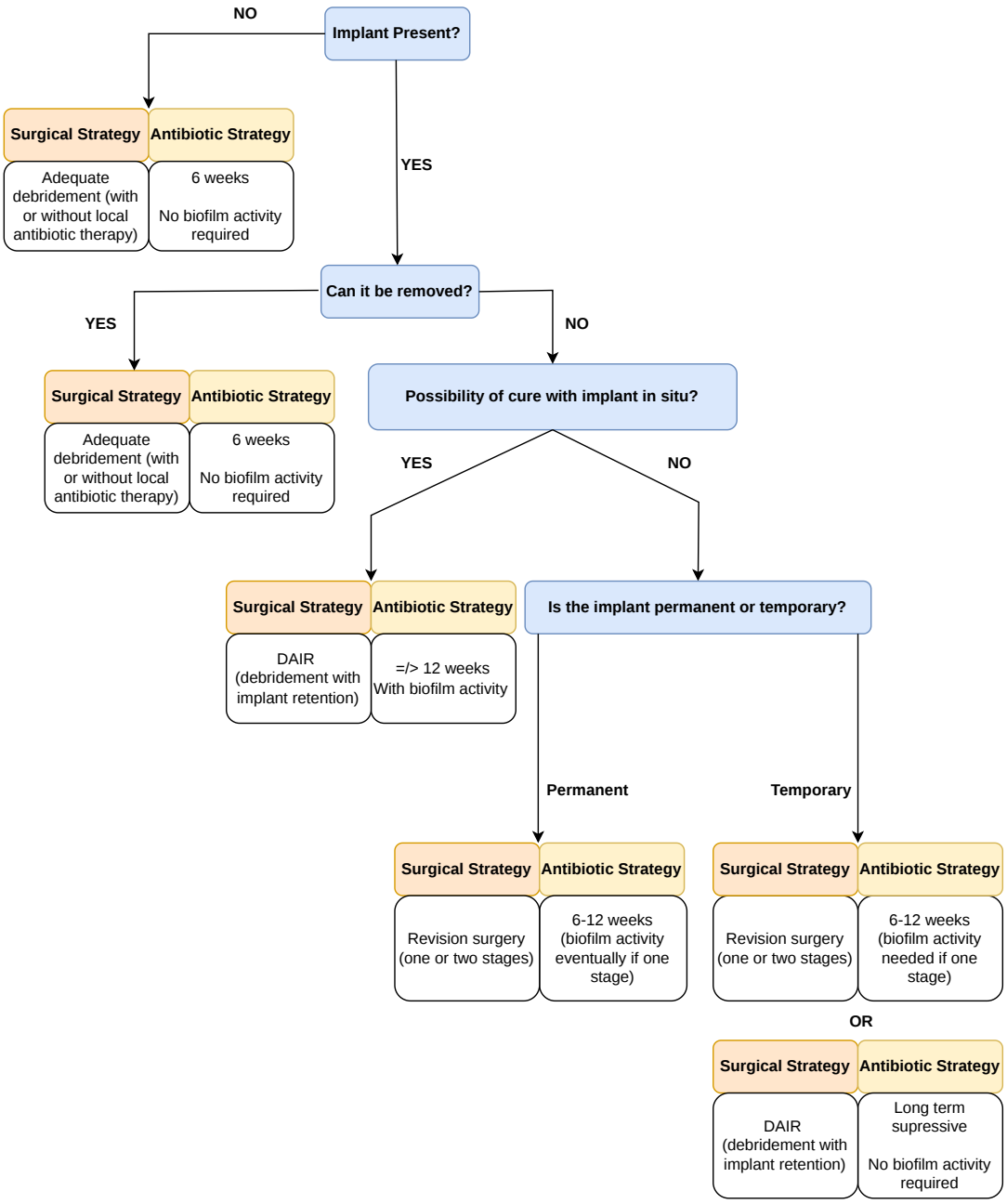

Figure 1. Treatment algorithm for bone and joint infection.

As outlined previously, the therapeutic strategy should follow a sequential algorithm based on four key questions. The answers to these determine the appropriate treatment pathway:

Is an implant present?

The presence of metal implants such as osteosynthesis hardware or prosthetic joints significantly influences the overall therapeutic strategy[6]. In the absence of an implant, both surgical and antibiotic treatment are typically more straightforward.

When no implant is present, management follows the principles of native osteomyelitis or septic arthritis, with surgical debridement, with or without the use of local antibiotic carriers and typically an antimicrobial course of approximately six weeks (frequently with 1–2 weeks of intravenous therapy followed by oral treatment, depending on clinical

response and source control)(figure 2)[5,8,10,11,17,21]. However, the optimal duration is not uniform across all implant-free infections, and in selected patients with adequate surgical source control and favourable clinical evolution, shorter treatment courses may be appropriate[11,28].



Figure 2. Illustrative example: An 85-year-old man with chronic distal femur osteomyelitis underwent radical debridement and local antibiotic therapy, achieving complete clinical resolution — illustrating the typical pathway of implant-free infection management.

If present, can it be safely removed, or is it required for stability or function?

If an implant is present but no longer required for mechanical support or joint function, it should be removed[8,12,17]. The persistence of osteosynthesis material in a healed construct offers no biomechanical advantage and may, in fact, perpetuate bacterial colonisation and biofilm persistence[8–10,17]. Once removed, the infection can be treated according to the principles of implant-free infection, including standard debridement and a six-week antibiotic course without the need for anti-biofilm agents. Early removal of unnecessary hardware not only facilitates more effective eradication of infection but also reduces the risk of chronic osteomyelitis and recurrence[5,6,8,12,17]. A classic example of this situation is a healed fracture or a fused spine arthrodesis where the implant no longer provides mechanical benefit. In these cases, implant removal should be performed, and subsequent treatment will follow the same algorithm as implant-free infection (figure 3)[5,8,18].

 — © 2026 The Author(s). CC BY 4.0

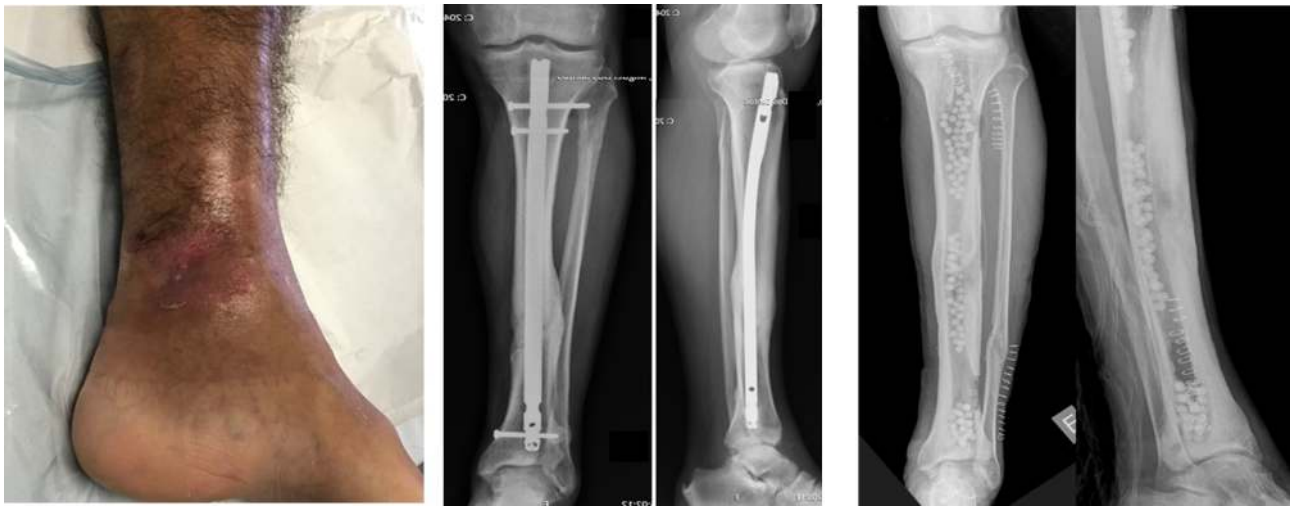

Figure 3. Illustrative example: A patient with a healed tibial fracture and a draining sinus underwent nail removal and debridement, with uncomplicated infection eradication — a typical scenario where hardware is unnecessary and should be removed.

Can the infection be eradicated while retaining the implant *in situ*?

When an implant is necessary, the next step is to determine whether curative treatment can be achieved without its removal. It is critical to evaluate the feasibility of implant retention, weighing the risk of persistent bacterial colonisation against the mechanical stability and functional integrity of the device[29–32]. This decision depends on several variables, depending on the specific clinical scenario (e.g. the conditions for PJI differ from those for FRI), including timing of infection (acute vs chronic), implant stability, adequacy of soft-tissue coverage, microbiological profile, and the availability of effective antibiotics. If these conditions are met, a DAIR procedure, followed by an appropriate course of anti-biofilm antibiotic therapy, may be a viable curative option. Although a 12-week course is commonly adopted in implant-associated infections treated with retention, duration should be adjusted on a case-by-case basis, acknowledging the heterogeneity of available evidence, and the possibility of a shorter course in carefully selected scenarios with adequate surgical control and favourable clinical response[11,28,33].

Figures 4 and 5 exemplify scenarios where retention is appropriate and curative outcomes are achievable.



Figure 4. Illustrative example: Acute fracture-related infection two weeks after tibial plateau fixation was successfully treated with DAIR and rifampicin-based therapy, demonstrating early curative potential.

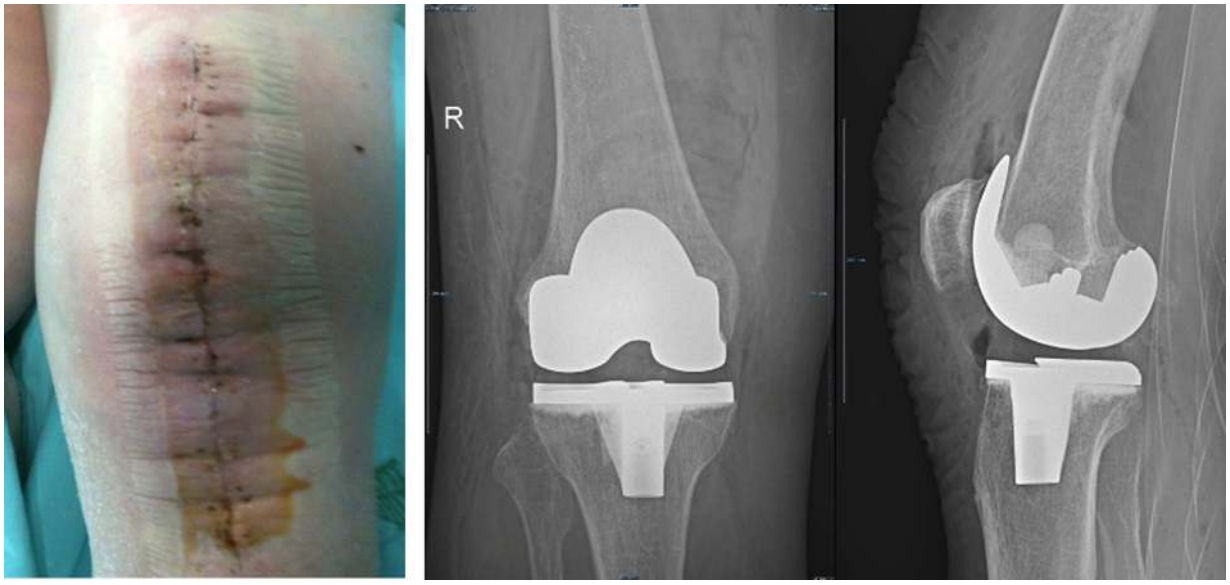

Figure 5. Illustrative example: An early postoperative PJI at three weeks after TKA (Total Knee Arthroplasty) achieved complete resolution with DAIR and targeted anti-biofilm therapy.

If required, is the implant needed permanently or temporarily?

If the implant is necessary for stability or function, it is essential to determine whether this requirement is temporary — as in fractures or spinal instrumentation with healing potential — or permanent, as with prosthetic joints[5,8,34].

If the need is temporary, or in cases where anti-biofilm antibiotics cannot be used—due to bacterial resistance, patient intolerance, drug interactions, or adverse effects—the infection is classified as "difficult-to-treat," and complete eradication is unlikely while the implant remains[10,11,35]. In these scenarios, suppressing the infection until the implant can be safely removed at a later stage instead of curing the infection might be a reasonable strategy[8,11,18,34,36].

If the implant is permanently needed, curative treatment usually requires implant exchange, performed either in one stage or two stages and appropriate antibiotic strategy. Single-stage revision is feasible when complete debridement, soft tissue coverage, known/ sensitive pathogens, and reconstruction are achievable in a single procedure (figure 6). Single-stage revision offers lower morbidity, fewer interstage complications (functional limitations, spacer-related fractures or dislocations), reduced healthcare burden, improved functional outcomes, and lower reinfection rates[30,37,38]. Postoperative anti-biofilm antibiotics should be administered for a total of 12 weeks[9,28,35,38,39].

Two-stage revision remains the standard for complex infections or difficult-to-treat pathogens (figure 7)[30,38,40]. The first stage involves implant removal, surgical debridement, multiple microbiological and histological sampling, and placement of an antibiotic-loaded spacer. The second stage consists of spacer removal, further debridement, and reimplantation. The interval allows eradication of infection before prosthetic reimplantation[28,38,40]. The decision regarding the exact timing for reimplantation remains controversial. Favourable ESR (erythrocyte sedimentation rate) and CRP (C-reactive protein) kinetics can serve as a decision tool, but complete normalisation is neither necessary nor sufficient to ensure a successful outcome[41–43].

 — © 2026 The Author(s). CC BY 4.0

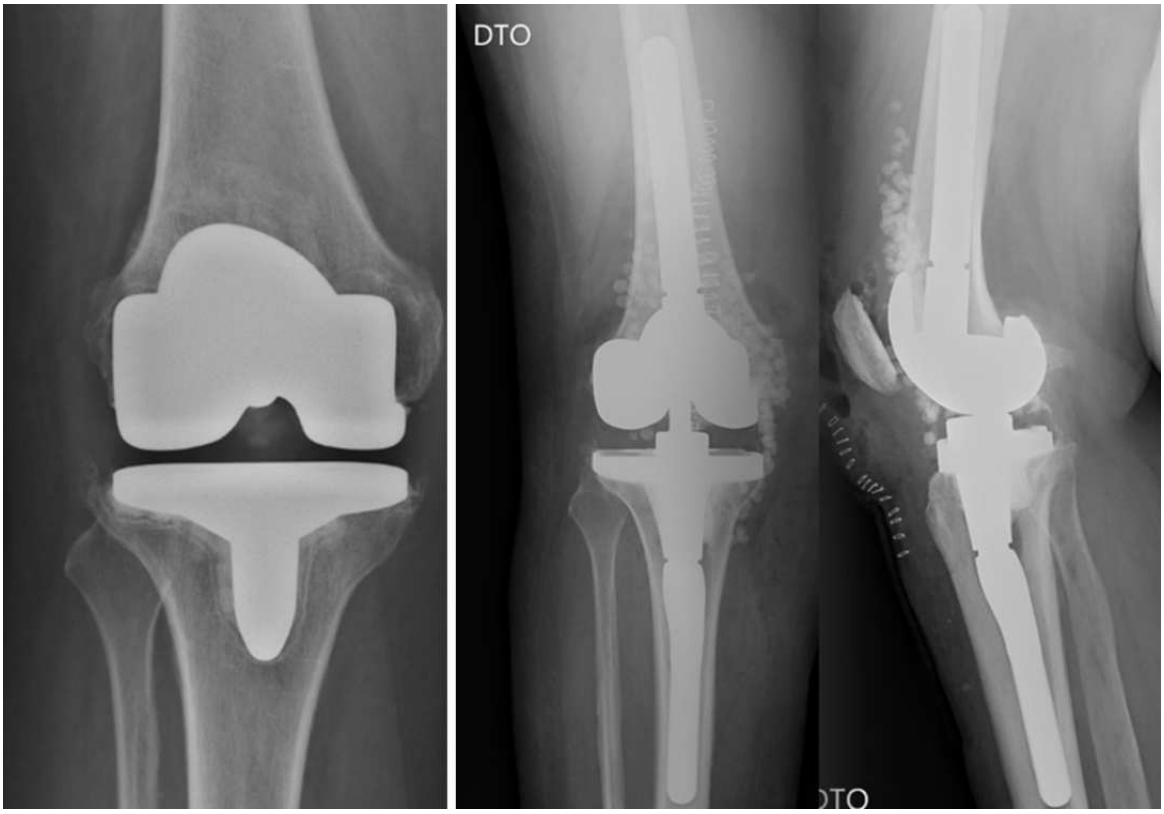

Figure 6. Illustrative example: A chronic knee PJI caused by *Serratia* was treated successfully with single-stage revision and targeted therapy.

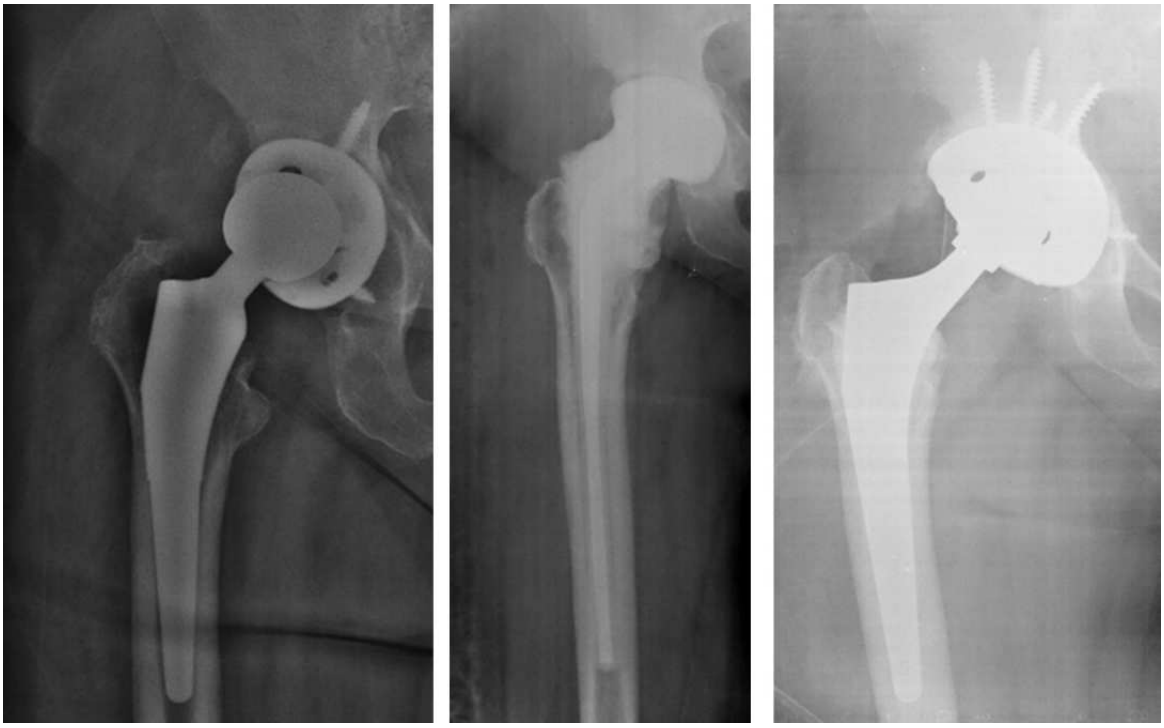

Figure 7. Illustrative example: A chronic hip PJI required initial explant and spacer placement, followed by delayed reimplantation, achieving stable reimplantation and infection control.

After the first stage, a 6-week course of antibiotics (no anti-biofilm activity required) is usually recommended. Once the infection is deemed to be cured, the second stage is performed (with or without an antibiotic holiday of a two-week period). According to the most recent scientific evidence, the

 — © 2026 The Author(s). CC BY 4.0

implementation of an antibiotic holiday before the second stage of revision has not demonstrated superiority in the treatment of these infections[44–47]. Therefore, in the absence of proven clinical benefit, patients undergoing an antibiotic holiday may be subjected to an unnecessary prolongation of their treatment[37,48–51]. Additional antibiotic therapy is adjusted based on second-stage microbiological findings. If cultures are negative, no further antibiotics are mandatory, although some authors may recommend an additional 6-week course. If second-stage cultures remain positive, anti-biofilm antibiotics should continue for 12 weeks post-reimplantation[9,10,28,35,37]. These durations reflect commonly adopted practices and consensus-based recommendations rather than fixed rules, and should therefore be regarded as reference frameworks rather than dogmatic standards, with final decisions guided by surgical source control, pathogen characteristics, host factors, and clinical evolution[11,28].

In highly selected cases, long-term antibiotic suppressive therapy, and not necessarily a cure, may even be considered[33,34].

Cases such as fractures where the implant need is temporary are slightly different. If implant removal is not possible without jeopardising stability, options include single-stage revision (figure 8) with immediate re-osteosynthesis, or two-stage management when infection is chronic, soft tissue is poor, or anti-biofilm agents are not available options (figure 9)[52–54]. Single-stage treatment is feasible when infection control is achievable and immediate mechanical stability can be obtained after osteosynthesis replacement[55–58]. Postoperatively, anti-biofilm antibiotics should be administered for a total of 12 weeks[54,56–58].

In the two-stage management, temporary fracture stabilisation is performed during the implant-free period, accompanied by 6 weeks of antibiotics without anti-biofilm activity[28,54,59]. Subsequently, two strategies can be adopted: reimplantation of osteosynthesis material followed by an additional 6-week course of anti-biofilm antibiotics if intraoperative cultures are negative, or 12 weeks if the cultures are again positive[54,59].

In cases where the implant is left in place, long-term antibiotic suppressive therapy may be considered until a future time when the implant can be removed, especially in one-stage exchanges or DAIR procedures where anti-biofilm antibiotics are not an option[33,60].

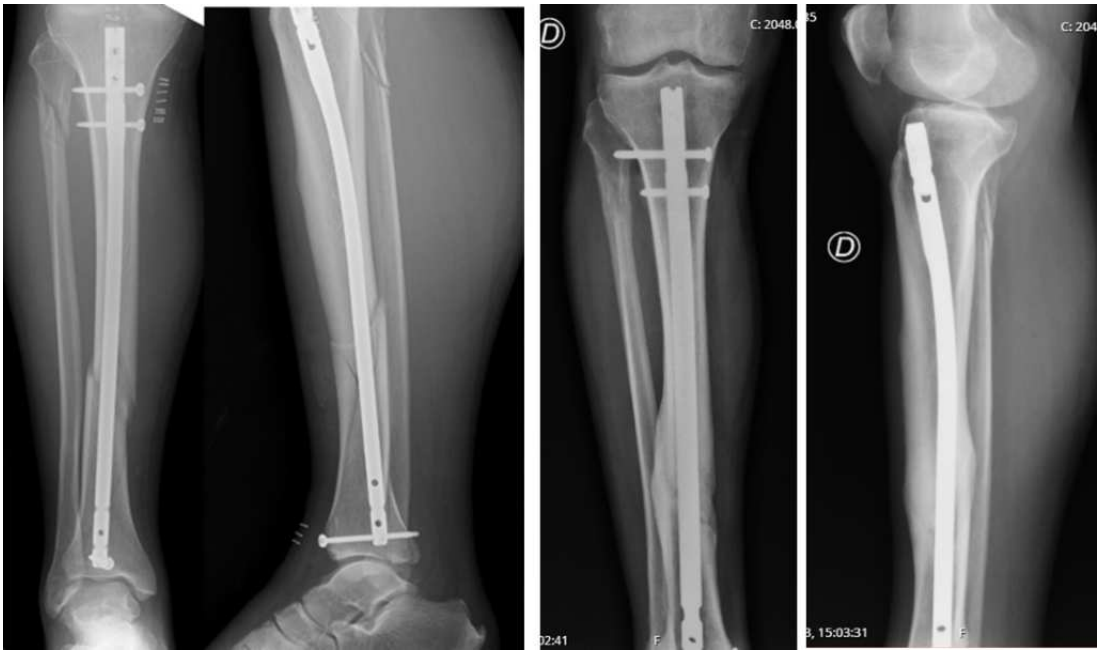

Figure 8. Illustrative example: A tibial diaphyseal fracture infection treated with single-stage exchange nailing achieved full consolidation and infection control.

 — © 2026 The Author(s). CC BY 4.0



Figure 9. Illustrative example: A proximal tibial FRI with non-union required staged removal, interim stabilisation, and delayed definitive fixation, achieving healing and infection eradication.

Conclusion

Bone and joint infections represent one of the most significant and complex conditions in musculoskeletal pathology. Their management requires the systematic application of the fundamental principles of infection treatment, which can only be effectively achieved through a multidisciplinary team dedicated to the integrated management of these complex conditions. Although this principle is universal, it becomes particularly important in borderline cases, such as those classified as "likely infection" according to the EBJIS definition, and in cases of clinical uncertainty, they should be managed as infected[1,14,61].

Interdisciplinary treatment algorithm for bone and joint infections needs structuring around two interdependent pillars: the surgical strategy and the corresponding antimicrobial plan. The indication, route, and duration of systemic and local antibiotic therapy must be defined in close alignment with the surgical approach—whether this involves debridement with implant retention (DAIR), staged revision, or complete hardware removal[3,29,31,52,55,60]. Each surgical option influences the antibiotic regimen, just as antimicrobial constraints may shape surgical decision-making. In parallel, antimicrobial duration should incorporate principles of antimicrobial stewardship, recognising existing uncertainties in some settings and the need for individualisation based on surgical strategy and clinical response[5,11,28,33].

Author Contributions

Tiago Torres and Manuel Vallarta: Conceptualization, writing—original draft, writing—review and editing.

Miguel Abreu and Ricardo Sousa: Supervision, writing—review and editing.

All authors have read and agreed to the published version of the manuscript.

Funding / Sponsorship

The authors received no financial support for the research, authorship, and/or publication of this article.

Ethics statement

This study is a review of previously published literature and did not involve human participants or animals. Therefore, ethical approval and informed consent were not required.

Conflicts of Interest

The authors declare no conflict of interest.

Table I. What the infectious disease specialist should know in bone and joint infection management.

Aspect	Key points
Diagnosis	Stop antibiotics at least 2 weeks before sampling. Avoid superficial swabs. Take ≥5 deep samples intraoperatively.
Surgery	Radical debridement is mandatory. Ensure mechanical stability and soft-tissue coverage.
Antibiotic therapy	Implant present → anti-biofilm agents are mandatory. Monotherapy only in rare cases. Rifampicin only under appropriate clinical conditions (dry surgical wound and favourable local progression) and should not be started in the immediate postoperative period.
DAIR	Feasible within the first 3–4 weeks. Requires stable implant, viable tissue, effective anti-biofilm antibiotics.
1 vs 2-stage	1-stage: acute infection, good tissues, sensitive pathogens. 2-stage: chronic infection, poor coverage, MDR pathogens.
Suppressive therapy	Consider when curative treatment is not possible. Monitor clinically + renal/hepatic function.

Abbreviations: DAIR, Debridement, Antibiotics, and Implant retention; MDR, Multidrug-Resistant.

Table II. Main surgical strategies in prosthetic joint infection management.

Strategy	Key points
DAIR	Indication: acute infection (<3–4 weeks). Required conditions: stable implant, good tissue, effective antibiotics. Antibiotic duration: 12 weeks with anti-biofilm agents. Success rate: 60.0%–90.0%.
1-stage revision	Indication: acute or early chronic infection. Required conditions: debridement, adequate soft-tissue coverage, stable reimplantation, known and susceptible pathogen. Antibiotic duration: 12 weeks. Success rate: 80.0%–90.0%.
2-stage revision	Indication: chronic or complex infection, MDR pathogens. Required conditions: explantation, spacer, delayed reimplantation. Antibiotic duration: 6 + 6 weeks (possibly extended). Success rate: 85.0%–95.0%.
Suppressive therapy	Indication: unremovable implant, fragile patient. Goal: control of progression rather than curative treatment. Antibiotic duration: indefinite. Outcome: disease control, not eradication.

Abbreviations: DAIR, Debridement, Antibiotics, and Implant retention; MDR, Multidrug-Resistant.

 — © 2026 The Author(s). CC BY 4.0

Table III. Common pitfalls to avoid in prosthetic joint infection management.

Avoid these common errors
Starting antibiotics before obtaining cultures when the patient is clinically stable.
Collecting only 1–2 intraoperative samples.
Treating biofilm infections without anti-biofilm agents.
Underestimating persistent wound drainage after arthroplasty.
Performing DAIR too late (after biofilm maturation).

Abbreviations: DAIR, Debridement, Antibiotics, and Implant retention.

References

1. McNally M, Sousa R, Wouthuyzen-Bakker M, Chen AF, Soriano A, Vogely HC, et al. The EBJIS definition of periprosthetic joint infection: a practical guide for clinicians. *Bone Joint J.* 2021;103-B(1):18–25. https://doi.org/10.1302/0301-620X.103B1.BJJ-2020-1381.R1
2. Baertl S, Metsemakers WJ, Morgenstern M, Alt V, Richards RG, Moriarty TF, Young K. Fracture-related infection. *Bone Joint Res.* 2021;10(6):351–353. https://doi.org/10.1302/2046-3758.106.BJR-2021-0167.R1
3. Zimmerli W, Trampuz A, Ochsner PE. Prosthetic-joint infections. *N Engl J Med.* 2004;351(16):1645–1654. https://doi.org/10.1056/NEJMra040181
4. Diniz SE, Vinha A, Ribau A, Soares D, Abreu MA, Sousa R. Is joint aspiration to rule out prosthetic joint infection required before every revision joint arthroplasty? Validation of institutional criteria using the new European Bone and Joint Infection Society definition. *Orthopaedic Spot.* 2024;AOP. https://doi.org/10.82189/spot.38
5. Depypere M, Morgenstern M, Kuehl R, Senneville E, Moriarty TF, Obremskey WT, et al. Pathogenesis and management of fracture-related infection. *Clin Microbiol Infect.* 2020;26(5):572–578. https://doi.org/10.1016/j.cmi.2019.08.006
6. Metsemakers WJ, Morgenstern M, McNally MA, Moriarty TF, McFadyen I, Scarborough M, et al. Fracture-related infection: a consensus on definition from an international expert group. *Injury.* 2018;49(3):505–510. https://doi.org/10.1016/j.injury.2017.08.040
7. Govaert GAM, Kuehl R, Atkins BL, Trampuz A, Morgenstern M, Obremskey WT, et al. Diagnosing fracture-related infection: current concepts and recommendations. *J Orthop Trauma.* 2020;34(1):8–17. https://doi.org/10.1097/BOT.0000000000001614
8. Metsemakers WJ, Kuehl R, Moriarty TF, Richards RG, Verhofstad MHJ, Borens O, et al. Infection after fracture fixation: current surgical and microbiological concepts. *Injury.* 2018;49(3):511–522. https://doi.org/10.1016/j.injury.2016.09.019
9. Beldman M, Löwik C, Soriano A, Albiach L, Zijlstra WP, Knobben BAS, et al. If, when, and how to use rifampin in acute staphylococcal periprosthetic joint infections: a multicentre observational study. *Clin Infect Dis.* 2021;73(9):1634–1641. https://doi.org/10.1093/cid/ciab426
10. Ferreira L, Pos E, Nogueira DR, Ferreira FP, Sousa R, Abreu MA. Antibiotics with antibiofilm activity – rifampicin and beyond. *Front Microbiol.* 2024;15:1435720. https://doi.org/10.3389/fmicb.2024.1435720
11. Depypere M, Kuehl R, Metsemakers WJ, Senneville E, McNally MA, Obremskey WT, et al. Recommendations for systemic antimicrobial therapy in fracture-related infection: a consensus from an international expert group. *J Orthop Trauma.* 2020;34(1):30–41. https://doi.org/10.1097/BOT.0000000000001626
12. Foster AL, Moriarty TF, Zalavras C, Morgenstern M, Jaiprakash A, Crawford R, et al. The influence of biomechanical stability on bone healing and fracture-related infection: the legacy of Stephan Perren. *Injury.* 2020;51(Suppl 2):S54–S61. https://doi.org/10.1016/j.injury.2020.06.044
13. Sousa R, Abreu MA. Advantages of a multidisciplinary team in the treatment of bone and joint infections. *Orthopaedic Spot.* 2025;AOP60. https://doi.org/10.82189/spot.60
14. McNally M, Sigmund I, Hotchen A, Sousa R. Making the diagnosis in prosthetic joint infection: a European view. *EFORT Open Rev.* 2023;8(5):253–263. https://doi.org/10.1530/EOR-23-0044
15. McNally M, Govaert G, Dudareva M, Morgenstern M, Metsemakers WJ. Definition and diagnosis of fracture-related infection. *EFORT Open Rev.* 2020;5:326–335. https://doi.org/10.1302/2058-5241.5.190072
16. Sousa R, Carvalho A, Santos AC, Abreu MA. Optimal microbiological sampling for the diagnosis of osteoar-

ticular infection. *EFORT Open Rev.* 2021;6:390–398. https://doi.org/10.1302/2058-5241.6.210011

17. Metsemakers WJ, Fragomen AT, Moriarty TF, Morgenstern M, Egol KA, Zalavras C, et al. Evidence-based recommendations for local antimicrobial strategies and dead space management in fracture-related infection. *J Orthop Trauma.* 2020;34(1):18–29. https://doi.org/10.1097/BOT.0000000000001615

18. Trampuz A, Zimmerli W. Diagnosis and treatment of infections associated with fracture-fixation devices. *Injury.* 2006;37(Suppl 2):S59–S66. https://doi.org/10.1016/j.injury.2006.04.010

19. Nelson A, Wright-Hughes A, Backhouse MR, et al; CODIFI collaborators. CODIFI (Concordance in Diabetic Foot Ulcer Infection): a cross-sectional study of wound swab versus tissue sampling in infected diabetic foot ulcers in England. *BMJ Open.* 2018;8:e019437. https://doi.org/10.1136/bmjopen-2017-019437

20. Vemu L, Sudhaharan S, Mamidi N, Chavali P. Need for appropriate specimen for microbiology diagnosis of chronic osteomyelitis. *J Lab Physicians.* 2018;10(1):21–25. https://doi.org/10.4103/JLP.JLP_14_17

21. Mifsud M, McNally M. Local delivery of antimicrobials in the treatment of bone infections. *Orthopaedics Trauma.* 2019;33(3):160–165. https://doi.org/10.1016/j.mporth.2019.03.007

22. Ferguson J, Diefenbeck M, McNally M. Ceramic biocomposites as biodegradable antibiotic carriers in the treatment of bone infections. *J Bone Jt Infect.* 2017;2:38–51. https://doi.org/10.7150/jbji.17234

23. Hoveidaei AH, Sabaghian A, Basirat E, Ramezani A, Shu HT, Conway JD. Local antibiotic delivery systems and their applications in orthopaedic surgery. *JB JS Open Access.* 2025;10(4). https://doi.org/10.2106/JBJS.OA.25.00157

24. Lucas J, Queirós J, Soares D, Carvalho A, Pereira F, Santos C, Sousa R, Araújo Abreu M. The impact of antibiotic therapy options and multidisciplinary approach in prosthetic joint infections. *Microorganisms.* 2025;13(10):2241. https://doi.org/10.3390/microorganisms13102241

25. Lazarinis S, Hailer N, Järhult J, Brüggemann A. Incidence of rifampicin resistance in periprosthetic joint infection: a single-centre cohort study on 238 patients. *Antibiotics (Basel).* 2023;12:1499. https://doi.org/10.3390/antibiotics12101499

26. Eriksson H, Lazarinis S, Järhult J, Hailer N. Early staphylococcal periprosthetic joint infection treated with debridement, antibiotics, and implant retention (DAIR): inferior outcomes in patients with staphylococci resistant to rifampicin. *Antibiotics (Basel).* 2023;12:1589. https://doi.org/10.3390/antibiotics12111589

27. Gachet B, Robineau O, Degrendel M, Bauer J, Cappeliez B, Bontemps E, Diarra A, Patoz P, Beltrand E, Senneville E, Lafon-Desmurs B. Fluoroquinolones vs. tetracycline agents combined with rifampicin for periprosthetic joint infections: a comparative study. *J Bone Jt Infect.* 2026;11(1):21–30. https://doi.org/10.5194/jbji-11-21-2026

28. Bernard L, Arvieux C, Brunschweiler B, Touchais S, Ansart S, Bru J-P, et al. Antibiotic therapy for 6 or 12 weeks for prosthetic joint infection. *N Engl J Med.* 2021;384(21):1991–2001. https://doi.org/10.1056/NEJMoa2020198

29. Wouthuyzen-Bakker M, Sebillotte M, Lomas J, Taylor A, Benavent E, Murillo O, et al. Clinical outcome and risk factors for failure in late acute prosthetic joint infections treated with debridement and implant retention. *J Infect.* 2019;78(1):40–47. https://doi.org/10.1016/j.jinf.2018.07.014

30. Citak M, Friedenstab J, Abdelaziz H, Suero EM, Zahar A, Salber J, Gehrke T. Risk factors for failure after 1-stage exchange total knee arthroplasty in the management of periprosthetic joint infection. *J Bone Joint Surg Am.* 2019;101(12):1061–1069. https://doi.org/10.2106/JBJS.18.00947

31. Sigmund IK, Ferry T, Sousa R, Soriano A, Metsemakers WJ, Clauss M, Trebse R, Wouthuyzen-Bakker M. Debridement, antimicrobial therapy, and implant retention (DAIR) as curative strategy for acute periprosthetic hip and knee infections: a position paper of the European Bone & Joint Infection Society (EBJIS). *J Bone Jt Infect.* 2025;10:101–138. https://doi.org/10.5194/jbji-10-101-2025

32. Morgenstern M, Kuehl R, Zalavras CG, McNally M, Zimmerli W, Burch MA, Vandendriessche T, Obremskey WT, Verhofstad MHJ, Metsemakers WJ. The influence of duration of infection on outcome of debridement and implant retention in fracture-related infection. *Bone Joint J.* 2021;103-B(2):213–221. https://doi.org/10.1302/0301-620X.103B2.BJJ-2020-1010.R1

33. Osmon DR, Berbari EF, Berendt AR, Lew D, Zimmerli W, Steckelberg JM, Rao N, Hanssen A, Wilson WR; Infectious Diseases Society of America. Diagnosis and management of prosthetic joint infection: clinical practice guidelines by the Infectious Diseases Society of America. *Clin Infect Dis.* 2013;56(1):e1–e25. https://doi.org/10.1093/cid/cis803

34. Zimmerli W. Clinical presentation and treatment of orthopaedic implant-associated infection. *J Intern Med.* 2014;276(2):111–119. https://doi.org/10.1111/joim.12233

35. Kramer TS, Soriano A, Tedeschi S, Chen AF, Tattevin P, Senneville E, et al. Should we use rifampicin in periprosthetic joint infections caused by staphylococci when the implant has been exchanged? A multicenter obser-

vational cohort study. *Clin Infect Dis.* 2023;ciad584. https://doi.org/10.1093/ofid/ofad491

36. Berkes M, Obremskey WT, Scannell B, Ellington JK, Hymes RA, Bosse M, et al. Maintenance of hardware after early postoperative infection following fracture internal fixation. *J Bone Joint Surg Am.* 2010;92(4):823–828. https://doi.org/10.2106/JBJS.I.00470

37. Sousa R, Carvalho A, Soares D, Abreu MA. Interval between two-stage exchanges: what is optimal and how do you know? *Arthroplasty.* 2023;5:33. https://doi.org/10.1186/s42836-023-00185-4

38. Blom AW, Lenguerrand E, Strange S, Noble SM, Beswick AD, Burston A, et al. Clinical and cost effectiveness of single-stage compared with two-stage revision for hip prosthetic joint infection (INFORM): pragmatic, parallel group, open label, randomised controlled trial. *BMJ.* 2022;379:e071281. https://doi.org/10.1136/bmj-2022-071281

39. Zimmerli W, Widmer AF, Blatter M, Frei R, Ochsner PE. Role of rifampin for treatment of orthopedic implant-related staphylococcal infections: a randomized controlled trial. *JAMA.* 1998;279(19):1537–1541. https://doi.org/10.1001/jama.279.19.1537

40. Ma CY, Lu YD, Bell KL, Wang JW, Ko JY, Wang CJ, Kuo FC. Predictors of treatment failure after 2-stage reimplantation for infected total knee arthroplasty: a 2- to 10-year follow-up. *J Arthroplasty.* 2018;33(7):2234–2239. https://doi.org/10.1016/j.arth.2018.02.007

41. Greidanus NV, Masri BA, Garbuz DS, Wilson SD, McAlinden MG, Xu M, et al. Use of erythrocyte sedimentation rate and C-reactive protein level to diagnose infection before revision total knee arthroplasty: a prospective evaluation. *J Bone Joint Surg Am.* 2007;89(7):1409–1416. https://doi.org/10.2106/JBJS.D.02602

42. Lee S-H, Chu C-T, Chang C-H, Hu C-C, Chen S-Y, Lu T-W, Lin Y-C. Do serum C-reactive protein trends predict treatment outcome in patients with knee periprosthetic joint infection undergoing two-stage exchange arthroplasty? *Diagnostics (Basel).* 2022;12(5):1030. https://doi.org/10.3390/diagnostics12051030

43. Jiang Q, Fu J, Chai W, Hao LB, Zhou YG, Xu C, Chen JY. Changes in serum markers failed to predict persistent infection after two-stage exchange arthroplasty. *J Orthop Surg Res.* 2020;15(1):382. https://doi.org/10.1186/s13018-020-01923-z

44. Akgun D, Muller M, Perka C, Winkler T. High cure rate of periprosthetic hip joint infection with multidisciplinary team approach using standardized two-stage exchange. *J Orthop Surg Res.* 2019;14(1):78. https://doi.org/10.1186/s13018-019-1113-8

45. Birlutiu RM, Mihalache M, Mihalache P, Cismasiu RS, Birlutiu V. Mid-term follow-up results after implementing a new strategy for the diagnosis and management of periprosthetic joint infections. *BMC Infect Dis.* 2021;21(1):807. https://doi.org/10.1186/s12879-021-06407-x

46. Ascione T, Balato G, Mariconda M, Rotondo R, Baldini A, Pagliano P. Continuous antibiotic therapy can reduce recurrence of prosthetic joint infection in patients undergoing 2-stage exchange. *J Arthroplasty.* 2019;34(4):704–709. https://doi.org/10.1016/j.arth.2018.12.017

47. Aali Rezaie A, Goswami K, Shohat N, Tokarski AT, White AE, Parvizi J. Time to reimplantation: waiting longer confers no added benefit. *J Arthroplasty.* 2018;33(6):1850–1854. https://doi.org/10.1016/j.arth.2018.01.073

48. Fraval A, Gould D, Yilmaz MK, Soriano A, Parvizi J. Antibiotic holiday in 2-stage exchange for periprosthetic joint infection: a scoping review. *J Bone Joint Surg Am.* 2025;107(22):2529–2536. https://doi.org/10.2106/JBJS.24.01275

49. Bejon P, Berendt A, Atkins BL, Green N, Parry H, Masters S, et al. Two-stage revision for prosthetic joint infection: predictors of outcome and the role of reimplantation microbiology. *J Antimicrob Chemother.* 2010;65(3):569–575. https://doi.org/10.1093/jac/dkp469

50. Tan TL, Kheir MM, Rondon AJ, Parvizi J, George J, Higuera CA, et al. Determining the role and duration of the "antibiotic holiday" period in periprosthetic joint infection. *J Arthroplasty.* 2018;33(9):2976–2980. https://doi.org/10.1016/j.arth.2018.04.019

51. Winkler T, Stuhlert MGW, Lieb E, Muller M, von Roth P, Preininger B, et al. Outcome of short versus long interval in two-stage exchange for periprosthetic joint infection: a prospective cohort study. *Arch Orthop Trauma Surg.* 2019;139(3):295–303. https://doi.org/10.1007/s00402-018-3052-4

52. Barros LH, Barbosa TA, Esteves J, Abreu MA, Soares D, Sousa R. Early debridement, antibiotics and implant retention (DAIR) in patients with suspected acute infection after hip or knee arthroplasty: safe, effective and without negative functional impact. *J Bone Jt Infect.* 2019;4(6):300–305. https://doi.org/10.7150/jbji.39168

53. Reilly RM, Robertson T, O'Toole RV, Manson TT. Are antibiotic nails effective in the treatment of infected tibial fractures? *Injury.* 2016;47:2809–2815. https://doi.org/10.1016/j.injury.2016.10.010

54. Lari A, Esmaeil A, Marples M, Watts A, Pincher B, Sharma H. Single versus two-stage management of long-bone chronic osteomyelitis in adults: a systematic review

and meta-analysis. *J Orthop Surg Res.* 2024;19:351. https://doi.org/10.1186/s13018-024-04832-7

55. Löwik CAM, Parvizi J, Jutte PC, Zijlstra WP, Knobben BAS, Xu C, et al. Debridement, antibiotics, and implant retention is a viable treatment option for early periprosthetic joint infection presenting more than four weeks after index arthroplasty. *Clin Infect Dis.* 2020;71(3):630–636. https://doi.org/10.1093/cid/ciz867

56. Amorosa LF, Buirs LD, Bexkens R, Wellman DS, Kloen P, Lorich DG, Helfet DL. A single-stage treatment protocol for presumptive aseptic diaphyseal nonunions: a review of outcomes. *J Orthop Trauma.* 2013;27:582–586. https://doi.org/10.1097/BOT.0b013e31828b76f2

57. Hackl S, von Rüden C, Trenkwalder K, Keppler L, Hierholzer C, Perl M. Long-term outcomes following single-stage reamed intramedullary exchange nailing in apparently aseptic femoral shaft nonunion with unsuspected proof of bacteria. *J Clin Med.* 2024;13:1414. https://doi.org/10.3390/jcm13051414

58. Chavan V, Kumar Bairwa VK, Jhanwar P, Bohra AK. Role of antibiotic-impregnated cement intramedullary nail in infected nonunion of long bone diaphyseal fractures. *J Orthop Traumatol Rehabil.* 2019;11:16–20.

59. Babhulkar S, Pande K, Babhulkar S. Nonunion of the diaphysis of long bones. *Clin Orthop Relat Res.* 2005;:50–56. https://doi.org/10.1097/01.blo.0000152369.99312.c5

60. Sousa R, Abreu MA. Treatment of prosthetic joint infection with debridement, antibiotics and irrigation with implant retention – a narrative review. *J Bone Jt Infect.* 2018;3(3):108–117. https://doi.org/10.7150/jbji.24285

61. Parvizi J, Gehrke T. Proceedings of the International Consensus Meeting on Musculoskeletal Infection. Philadelphia: Data Trace Publishing; 2018.

 — © 2026 The Author(s). CC BY 4.0